

Case Report

Usefulness of the Echo-Guided Parasternal Tunneling for the Subcutaneous Implantable Cardioverter-Defibrillator Implantation In High Body Mass Index Patient

Shingo Sasaki, MD, PhD*, Kimitaka Nishizaki, MD, PhD, Yuji Ishida, MD, PhD, Yuichi Toyama, MD, PhD, Takashi Yokota, MD, PhD, Hirofumi Tomita, MD, PhD

Department of Cardiology and Nephrology, Hirosaki University Graduate School of Medicine, Hirosaki, Japan

***Corresponding Author:** Shingo Sasaki, MD, PhD, Department of Cardiology and Nephrology, Hirosaki University Graduate School of Medicine, 5 Zaifu-cho, Hirosaki, 036-8562, Japan, E-mail: sshingo@hirosaki-u.ac.jp

Received: 23 October 2020; **Accepted:** 02 November 2020; **Published:** 30 November 2020

Abstract

Successful implantation of the subcutaneous implantable cardioverter-defibrillator (S-ICD) (EMBLEM, Boston Scientific, Marlborough, Massachusetts, USA) in highly obese patients represented by high body mass index (BMI) is extremely difficult due to inappropriate parasternal tunneling. We attempted echo-guided parasternal tunneling during S-ICD implantation for a 59-year-old high BMI patient and succeeded in placing the lead on the optimal position.

Keywords: S-ICD; Echo-guided parasternal tunneling; High BMI

1. Case Report

Successful implantation of the subcutaneous implantable cardioverter-defibrillator (S-ICD) (EMBLEM, Boston Scientific, Marlborough, Massachusetts, USA) in highly obese patients represented by high body mass index (BMI) is extremely difficult due to inappropriate parasternal tunneling. Inappropriate parasternal tunneling, which defined by the existence of fat tissue between the shock-coil and surface of the sternum, has been shown to increase shock impedance and reduce the successful defibrillation [1, 2].

A 59-year-old male with left ventricular systolic dysfunction after aortic and mitral valve replacement underwent S-ICD implantation by two-incision technique [3]. The procedure was performed under conscious sedation using continuous intravenous infusion of midazolam with intermittent intravenous administration of fentanyl, and local anesthesia. The S-ICD generator was placed in intermuscular space between the serratus anterior muscle and the latissimus dorsi muscle via a lateral sub-mammary incision. Because the patient was highly obese (BMI 30.4 kg/m²) and the surface of the sternum was not fully recognized due to large amount of subcutaneous fat, we attempted a novel echo-guided parasternal tunneling using the electrode delivery system (EDS 4712, Boston Scientific, Marlborough, Massachusetts, USA) (Figure 1). The transthoracic echo (Vivid iq, GE healthcare) demonstrated subcutaneous structure such as sparse fat tissue, curved surface of sternum, and sternocostal joints. The tip of the insertion tool was also visible (Figure 2).

We confirmed that the tip of the insertion tool was in contact with the surface of the sternum or sternocostal joints by echo and succeeded deep tunneling accurately. Defibrillation test was performed during the procedure and successfully terminated by a single 65 J shock. The time to shock was 13.2 seconds and the post-shock impedance was 65 ohms.

In the S-ICD implantation, achievement of the posterior generator position and accurate substernal tunneling, which defined as a lack of intervening fat between the coil and/or the generator and the underlying fascia, are expected to be predictors of successful defibrillation. Therefore, echo-guided parasternal tunneling may be a useful method for S-ICD implantation in high BMI patients.

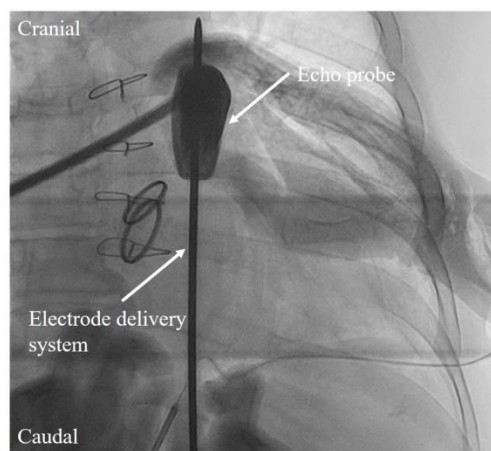


Figure 1: Fluoroscopic image during echo-guided parasternal tunneling using the electrode delivery system.

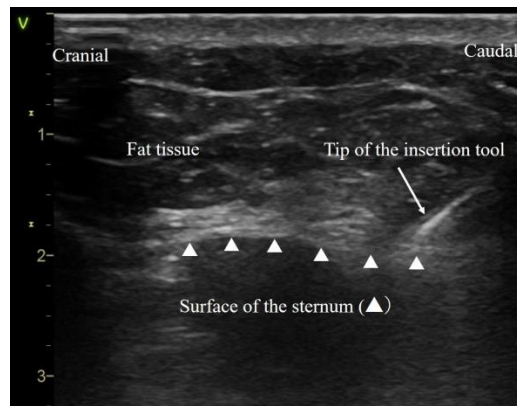


Figure 2: Demonstration of subcutaneous structure such as sparse fat tissue, curved surface of sternum, and sternocostal joints by transthoracic echo.

2. Sources of Funding

There was no financial support for this study.

3. Conflict of Interest

Dr. Shingo Sasaki has received research grant supports from Medtronic Japan Co., Ltd. and Fukuda Denshi Kitatohoku Hanbai Co., Ltd. and BIOTRONIK Japan Co., Ltd. Dr. Shingo Sasaki has received scholarship donation from Japan Lifeline Co., Ltd and Boston Scientific Japan Co., Ltd. The all other authors have no relevant disclosures.

References

1. Heist EK, Belalcazar A, Stahl W, et al. Determinants of subcutaneous implantable cardioverter-defibrillator efficacy: a computer modeling study. *JACC Clin Electrophysiol* 3 (2017): 405-414.
2. Amin AK, Gold MR, Burke MC, et al. Factors associated with high-voltage impedance and subcutaneous implantable defibrillator ventricular fibrillation conversion success. *Circ Arrhythm Electrophysiol* (2019): 12:e006665.
3. Knops RE, Olde Nordkamp LR, de Groot JR, Wilde AA. Two-incision technique for implantation of the subcutaneous implantable cardioverter-defibrillator. *Heart Rhythm* 10 (2013): 1240-1243.

Citation: Shingo Sasaki, Kimitaka Nishizaki, Yuji Ishida, Yuichi Toyama, Takashi Yokota, Hirofumi Tomita. Usefulness of the Echo-Guided Parasternal Tunneling for the Subcutaneous Implantable Cardioverter-Defibrillator Implantation In High Body Mass Index Patient. *Archives of Clinical and Medical Case Reports* 4 (2020): 1116-1118.



This article is an open access article distributed under the terms and conditions of the [Creative Commons Attribution \(CC-BY\) license 4.0](https://creativecommons.org/licenses/by/4.0/)