



## Case Report

# Urgent Appendectomy Performed Along with Hematopoietic Cell Transplantation (HCT) for a Patient with Severe Aplastic Anaemia – A Case Report

Sondus Alsharidah<sup>1\*</sup>, Samar Ousia<sup>2</sup>, Elshazly Abdelhafez<sup>1</sup>, Brigitta Antoun<sup>1</sup>, Dalal Alshemmeri<sup>1</sup>, Hassan Khalil<sup>3</sup>, Medhat Askar<sup>4, 5, 6</sup>

<sup>1</sup>Paediatric Stem Cell Transplant Unit, Department of Paediatric Haematology oncology, NBK children's specialized hospital, Kuwait

<sup>2</sup>Stem Cell Transplant Unit, Department of hematology and bone marrow transplant, Kuwait Cancer Centre, Kuwait

<sup>3</sup>Surgical department, Sabah Hospital, Kuwait

<sup>4</sup>Department of pathology and laboratory medicine, Texas health science Center, college of medicine, Texas, USA

<sup>5</sup>Cell processing laboratory, Baylor University Medical Center, Texas, USA

<sup>6</sup>Director of Clinical Services, The National Marrow Donor Program (NMDP)/BeTheMatch, MN, USA

**\*Corresponding Author:** Sondus Alsharidah, Paediatric Stem Cell Transplant Unit, Paediatric Haematology oncology department, NBK children's specialized hospital, Kuwait

**Received:** 01 April 2022; **Accepted:** 23 April 2022; **Published:** 29 April 2022

**Citation:** Sondus Alsharidah, Samar Ousia, Elshazly Abdelhafez, Brigitta Antoun, Dalal Alshemmeri, Hassan Khalil, Medhat Askar. Urgent Appendectomy Performed Along with Hematopoietic Cell Transplantation (HCT) for a Patient with Severe Aplastic Anaemia – A Case Report. Archives of Clinical and Medical Case Reports 6 (2022): 324-330.

### Abstract

A 14-year-old male was waiting for hematopoietic cell transplantation for severe aplastic anaemia. The night prior

to the transplant he unexpectedly developed acute appendicitis. A couple of hours earlier to the emergency laparoscopic appendectomy, he had peripheral blood stem

cell (PBSC) transplant with no complications.

**Keywords:** Acute Appendicitis; HCT; Aplastic Anaemia; Pancytopenia; Appendectomy; Case Report

## 1. Introduction

Aplastic anaemia is a syndrome of hematopoietic failure resulting from injury leading to diminished or absent hematopoietic precursors or hypocellularity in the bone marrow and associated pancytopenia [1]. It is a rare, life-threatening haematological disorder that occurs across all age groups [2]. The most common complications of aplastic anaemia include bleeding, infections, or transformation to lymphoproliferative disorders [1]. The prognosis for patients with aplastic anaemia has markedly improved recently because of better treatment and supportive measures. For idiopathic severe aplastic anaemia (SAA), a matched sibling donor (MSD) hematopoietic cell transplant (HCT) is the treatment of choice [3].

Pancytopenia and bone marrow suppression, due to aplastic anemia increase the susceptibility to infections, particularly infections of the abdomen [4]. Neutropenic Enterocolitis (NE) and acute appendicitis are life-threatening conditions, that develop in children with severe or prolonged neutropenia and are often hard to diagnose [5]. Hematopoietic cell transplantation (HCT) for patients with active infections generally has poor outcomes, because of high infection-related and transplant-related mortality. Appendicitis is an uncommon complication of SAA; it is an inflammation of the appendix, which leads to an increased diameter of the organ to  $\geq 0.6$  cm and corresponding clinical signs [6]. Here, we report a case of severe aplastic anaemia complicated by the development of acute appendicitis on the night of stem cell transplantation.

## 2. Case Presentation

A 14-year-old male presented with ecchymotic skin patches, pallor, lethargy, investigated and diagnosed with severe aplastic anaemia (bone marrow aspiration: cellularity  $<10\%$  and no blast cells, no evidence of PNH, depressed all precursors) 2 weeks later he had COVID-19 that required hospitalisation for 2 weeks. During all this period he was blood products transfusion dependent every other day, then started on oral eltrombopag (thrombopoietin receptor agonist) 50 mcg, twice a day on increment doses with poor response over 6 weeks. The patient serum ferritin was 3400 mg/L then started on iron chelation therapy (IV deferoxamine infusion 50 mg/kg) 4 times a week while being inpatient due to the high demand of blood products transfusions.

Furthermore, he was prepared for hematopoietic cell transplantation with matched related sibling donor (his brother) and conditioned with Flu, Cy, ATG and GVHD prophylaxis cyclosporin and methotrexate. Although the patient was booked for fresh bone marrow stem cell transplant, we cryopreserved peripheral blood stem cell (PBSC) prior to the chemotherapy conditioning following EBMT recommendations for all patients during the COVID-19 pandemic [7].

On day -1 the patient developed severe acute abdominal pain on the right iliac fossa associated with constipation and vomiting, x-ray abdomen and ultrasound abdomen showed no abnormalities, but abdominal pain persisted, so he was evaluated by the surgeon and wanted to rule out appendicitis by CT abdomen with contrast, that showed later the appendix with retrocaecal position presented as tubular dilated blind end structure measuring about 8 mm in calibre fluid filled showing unilateral mural thickness reaching 3 mm with

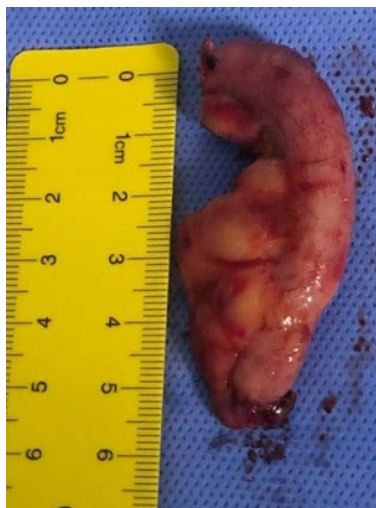mucosal hyperenhancement associated with minimal pelvic fluid collection surrounding fat stranding and few mildly enlarged sub mesenteric regional lymph nodes, this is suggestive of acute appendicitis, the ascending colon and ileocecal junction and to a lesser extent the ascending colon showed diffuse mural thickening with fat halo sign likely indicating neutropenic colitis, his complete blood count WBC  $0.01 \times 10^9/L$ , Haemoglobin (HB) 75 g/L platelets  $8 \times 10^9/L$ .

After diagnosing the patient clinically and radiologically with acute appendicitis and neutropenic colitis he was kept nil per oral, on IV metronidazole IV 7.5 mg/kg /TDS and Amikacin IV 15 mg/kg/d and piperacillin tazobactam IV 4.5 g/QDS, then he was prepared for the surgical procedure as he was anaemic and thrombocytopenic. Here the decision of stem cell transplant was taken to be done prior to the surgical procedure, so the patient had PBSC transplantation with CD34 cell dose  $4.4 \times 10^6 /KG$ , viability 85%. The SCT started after pre-medications (steroids, paracetamol, antihistamine) given to the patient with the vitals were stable throughout with no immediate complications. The parents were consented with high-risk consent for an urgent laparoscopic appendectomy that was performed 2 hours after the HCT. The patient was continued on antibiotics for 7-10 days post-laparoscopic appendectomy surgery, and pain was controlled with opioids and paracetamol, we noticed

hypokalaemia that was corrected with potassium supplements. The histopathology of the appendix resected revealed acute suppurative appendicitis (Figure 1).

The patient was cared for post HCT. and post-surgical procedure, so the oral fluids were resumed within 2-3 days with good tolerance. Regarding the HCT care: he engrafted platelets on day 12 and neutrophils within day 16. We noticed the patient had anxiety attacks and aggressive behaviour that required psychiatric management, he was started temporarily on anxiolytics for 2 weeks. The patient remained in the hospital for management and close monitoring. Then was discharged home on day +26 post SCT, day+26 Post endoscopic appendectomy, follow up is scheduled twice a week. Day + 28 Chimerism: 94.4% donor cells. The patient continued on regular follow up, and occasionally requiring hydration at the day care, the follow up was every 4 weeks in the clinic. with good outcome of his Chimerism day +90 and +360 is 93, 4%, 97.9% respectively.

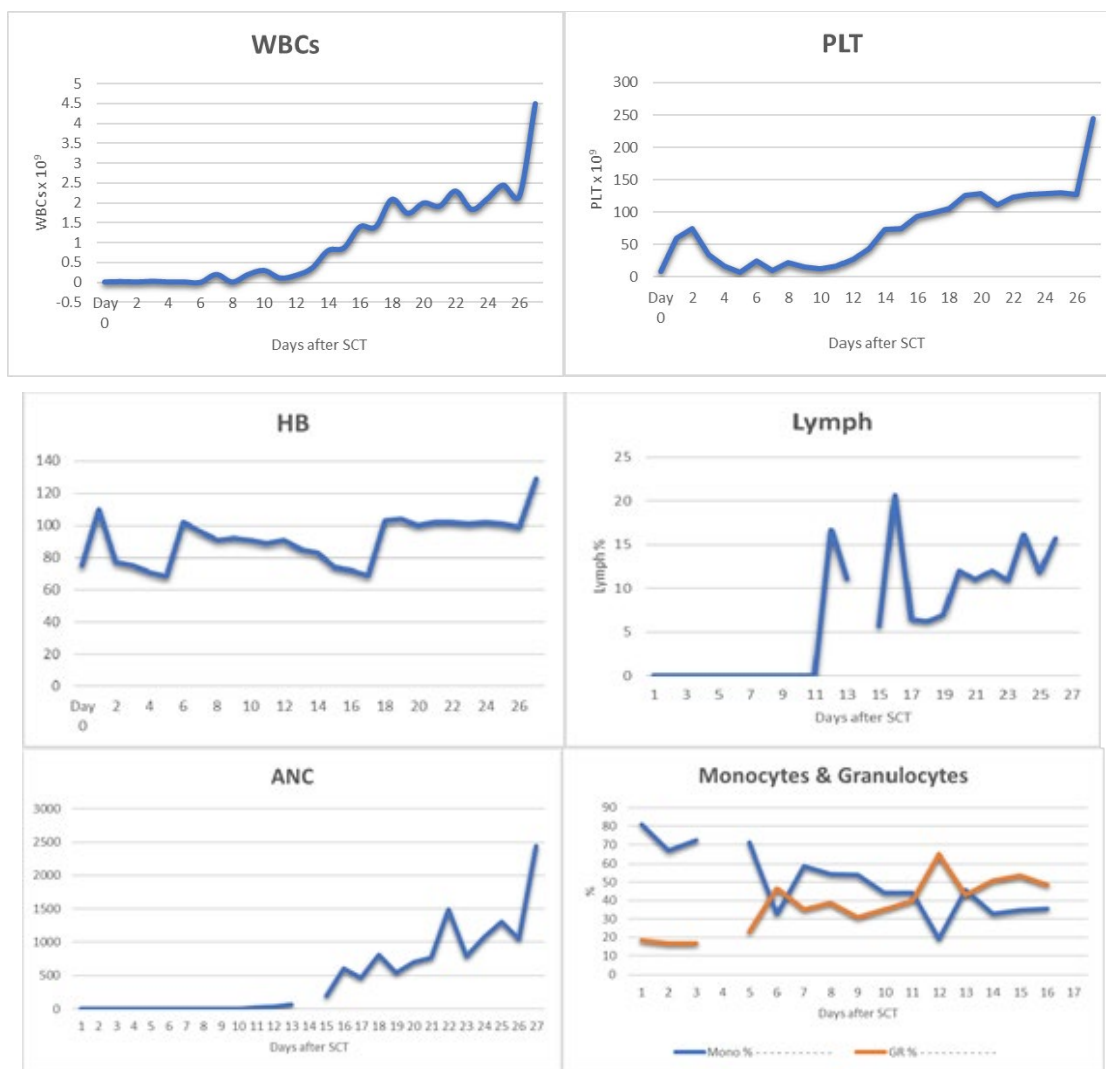
Immunoreconstitution was within 5 months of transplant CD 4 absolute count 335 cells/ ul. There was iron overload, serum ferritin (1884 ng/ml) venesection was started for him, last serum ferritin 584 ng/ml, last CBC: WBC  $7.4 \times 10^9/L$  neutrophil  $3.7 \times 10^9/L$ , HB 139 g/L platelets  $223 \times 10^9/L$ . Patient is off immunosuppression medication after 1 year of transplant and the chimerism is stable all through.



**Figure 1:** features the removed appendix from the patient's abdomen.

<b>Complete Blood Count</b>	WBCs	$0.01 \times 10^9$
	Hemoglobin concentration	75 g/L
	Platelet count	$8 \times 10^9$
	Absolute Neutrophil Count	0
<b>Liver Function Tests</b>	Bilirubin	15.4 umol/L
	AST	9.1 U/L
	ALT	9 U/L
<b>Renal Function Tests</b>	Sodium (Na)	139 mmol/L
	Potassium (K)	3.92 mmol/L
	Urea (U)	3.4 mmol/L
	Creatinine (Cr)	37 umol/L
	Magnesium (Mg)	0.77 mmol/L
	Serum Calcium (Ca)	2.12 mmol/L
	Phosphorus (Ph)	0.74 mmol/L
<b>Coagulation Profile</b>	Prothrombin Time (PT)	21.6 Secs high
	INR	1.42
	Partial thromboplastintime (PTT)	49.2 Secs high
<b>D.Dimer</b>	414 ng/ml high	
<b>CRP</b>	153 mg/L high	

**Table 1:** Shows the blood test results during the diagnosis of appendicitis.



**Chart 1:** CBC showing engraftment following the SCT up to discharge.

### 3. Discussion

Appendicitis is a life-threatening, rare complication that is reported during hematopoietic cell transplantation (HCT) with no set standard of care [8, 9]. Severe prolonged neutropenia secondary to aplastic anaemia, chemotherapy and immunosuppressant is probably the culprit as they increase the risk of gastrointestinal infections [5]. Gastrointestinal infections observed in this patient

population represent approximately 30% of neutropenic infections [10]. Owing to the rarity of this condition, there is not enough data on the incidence of acute appendicitis in HCT patients, nor there is enough evidence to support optimal management. There is limited literature on acute appendicitis in the setting of hematopoietic cell transplant [10-12]. Most data published in the literature comes from case reports or case series [8].

Even though appendicitis in stem cell transplant HSCT is uncommon, it is a challenging complication, both in diagnosis and management. The Alvarado Scoring System (the MANTRELS acronym stands for ‘Migration, Anorexia-acetone, Nausea-vomiting, Tenderness in the right quadrant, Rebound pain, Elevation of temperature, Leukocytosis, Shift to the left), which is shortened to ASSMANTRELS, has been used to diagnose acute appendicitis [3]. However, acute appendicitis occurred in HSCT patients during the neutropenic phase. The indexes of leukocytosis and shift to the left (LS) of the ASS-MANTRELS did not apply to these patients. A new scoring system named ASS-MANTREU includes symptoms, signs, and the ultrasound examination result [13]. There is still a debate whether surgical intervention or conservative antibiotic therapy is the best approach in such a population.

Several studies and case reports advocate the benefits of conservative treatment with antibiotic therapy. However, other studies have shown that surgical management of acute appendicitis in neutropenic patients can be safely performed and is the most effective therapeutic modality despite having neutropenia [6]. The study of Mortellaro et al. suggested that timely surgical interventions within a day of diagnosis could be done safely in neutropenic patients [14]. Nevertheless; appendectomy in this patient population is not without risks. Wound infection, delayed healing, and hemorrhagic complications are all factors to be considered. Other studies recommend a multidisciplinary team assessment of each case to decide on the best approach to treat appendicitis on a case-by-case basis [8]. Surgical appendectomy remains the treatment of choice for appendicitis and in line with treatment guidelines of the American College of Surgeons and World Society of Emergency Surgery [15, 16]. In our case, the decision was made based on the patient’s clinical

status and he was successfully treated for appendicitis using surgical management with no complications.

#### 4. Conclusion

In conclusion, even though acute appendicitis in hematopoietic stem cell transplant patients is a rare occurrence, a critical complication should be addressed and managed in a timely fashion to avoid further complications. The choice to surgically remove the appendix or use conservative antibiotic therapy remains subject to each patient’s clinical scenario.

#### Declaration of Conflicting Interests

The author declared no potential conflicts of interest with respect to the research, authorship, and/or publication of this article.

#### Informed Consent

The patient’s mother provided written informed consent for the patient information.

#### Acknowledgements

Funded by Gilead Sciences without any interpretation of data.

#### References

1. Moore CA, Krishnan K. Aplastic Anemia. In: StatPearls (2022).
2. DeZern AE, Guinan EC. Aplastic anaemia in adolescents and young adults. *Acta Haematol* 132 (2014): 331-339.
3. Samarasinghe Sujith, Webb David. (2012). How I manage aplastic anaemia in children. *British journal of haematology* 157 (2012): 26-40.

4. Ali A, Alhindi S, Alalwan A A, et al. Acute Appendicitis in a Child with Acute Leukemia and Chemotherapy-Induced Neutropenia: A Case Report and Literature Review. *Cureus* 12 (2020): e8858.
5. Bulent Alioglu, Zekai Avci, Figen Ozcay, et al. Neutropenic Enterocolitis in Children with Acute Leukemia or Aplastic Anemia. *Int J Hematol* 86 (2007): 364-368.
6. Von Mersi H, Benkö T, Boztug H, et al. Diagnosis and management of acute appendicitis in 21 pediatric hematology and oncology patients at a tertiary care cancer center. *Scientific reports* 11 (2021): 1-6.
7. Coronavirus Disease Covid-19: Ebmt Recommendations Version 14 (2021)
8. Wright Z, Essien F, Renshaw J, et al. Appendiceal disease in hematopoietic cell transplantation. *Clin Case Rep* 10 (2022): e05047.
9. Wright Zachary, Wiggins Michael, Renshaw John, et al. Appendiceal Disease Peri-Transplant. *Biology of Blood and Marrow Transplantation* 22 (2016): S296-S297.
10. Koretz MJ, Neifeld JP. Emergency surgical-treatmentfor patients with acute leukemia. *Surg Gynecol Obstet* 161 (1985): 149-151.
11. Forghieri F, Luppi M, Narni F, et al. Acute appendicitis in adult neutropenic patients with hematologic malignancies. *Bone Marrow Transplant* 42 (2008): 701-703.
12. Kontoyiannis DP, Mathur M, ChenY-B, et al. Case records of the Massachusetts General Hospital. Case 13-2014. A 41-year-old man with fever and abdominal pain after stem-cell transplantation. *N Engl J Med* 370 (2014): 1637-1646.
13. Zhang Q, Zhou Y, Majaw J, et al. Acute appendicitis in leukaemia patients undergoing haematopoietic stem cell transplantation during the neutropaenic phase: a case series from a single BMT centre in China. *Bone Marrow Transplant* 53 (2018): 219-222.
14. Mortellaro V, Juang D, Fike FB, et al. Treatment ofappendicitis in neutropenic children. *J Surg Res* 170 (2011): 14-16.
15. Ruffolo C, Fiorot A, Pagura G, et al. Acute appendicitis: what is the gold standard oftreatment?. *World J Gastroenterol* 19 (2013): 8799- 8807.
16. Sartelli M, Viale P, Catena F, et al. 2013 WSES guidelines for management of intra- abdominal infections. *World J Emerg Surg* 8 (2013): 3.



This article is an open access article distributed under the terms and conditions of the [Creative Commons Attribution \(CC-BY\) license 4.0](https://creativecommons.org/licenses/by/4.0/)