

Case Report

The Advantage of High Throughput Sequencing for the Diagnosis of Child Shwachman-Diamond Syndrome

Na Li, Li Zhang, Xin Bo Yu, Jing Zhu and Zheng Juan Liu*

Department of Pediatrics, the Second Affiliated Hospital of Dalian Medical University, 467 Zhongshan Road, Shahekou District, Dalian 116027, China

***Corresponding Author:** Dr. Zheng Juan Liu, Department of Pediatrics, the Second Affiliated Hospital of Dalian Medical University, 467 Zhongshan Road, Shahekou District, Dalian 116027, China, Tel: 0411-84671291-5100; Fax: 0411-84672130; E-mail: liuzj625@163.com

Received: 31 July 2019; **Accepted:** 14 August 2019; **Published:** 18 November 2019

Abstract

Background: Shwachman-Diamond syndrome is a rare autosomal recessive disorder with an incidence of 1/76000. It is caused by biallelic pathogenic variants in SBDS allele, characterized by pancreatic exocrine insufficiency, abnormal blood system, and skeletal abnormalities. Here, we describe the diagnosis of a child with Shwachman-Diamond syndrome and discuss the main clinical symptoms of Shwachman-Diamond syndrome and the importance of genetic testing for its diagnosis.

Case description: A 5.5 year-old boy was hospitalized in our ward of the Second Affiliated Hospital of Dalian Medical University due to short stature. The patient was also found to have significantly reduced or lack of neutrophils, repeated infections, and thrombocytopenia. Clinical symptoms suggested the patient suffered from Shwachman-Diamond syndrome. This was confirmed two years later by gene sequencing: compound heterozygous pathogenic variants exon2 deletion and c.258+2T>C in SBDS gene were detected. They were verified by qPCR or Sanger sequencing.

Conclusion: Shwachman-Diamond Syndrome may have pathological changes in multiple systems and is characterized by pancreatic exocrine dysfunction and abnormal blood cells. The clinical symptoms include growth retardation, intermittent or persistent cytopenia, repeated infections due to neutropenia. Shwachman-Diamond Syndrome is a genetic disease and gene sequencing is helpful to confirm the diagnosis.

Keywords: Shwachman-Diamond syndrome; Growth retardation; Neutropenia; Thrombocytopenia; High throughput Sequencing

1. Introduction

Shwachman-Diamond syndrome (SDS) is a rare and degenerative genetic disease. It is an autosomal recessive disorder caused by mutations in the SBDS allele, with various clinical symptoms. This case report describes the treatment of a child with SDS and the process of its diagnosis. The report also analyzes the main clinical symptoms and emphasizes the importance of high throughput sequencing for its diagnosis.

2. Clinical Information

A 5.5 year-old boy was hospitalized in March 2016 due to post-natal neutropenia accompanied by growth retardation. He was the first born of his mother and was delivered naturally at the 34th week of pregnancy. His birth weight was 2.0 kg with a height of 45 cm, and the Apgar score was 9 points. He was breastfed and had septicemia in the neonatal period. He suffered repeated infections with neutropenia, red blood cells and platelets were normal. The parents were in good health. The father was 183 cm and the mother was 165 cm in height. There is no family history of agranulocytosis and short stature. T: 36.2°C, P: 100/min, R: 24/min, BP: 80/60 mmHg, BW: 14 kg, Ht: 98.5 cm. No abnormalities were found in the physical examination. The absolute neutrophil count has been low ($0.2-0.9 \times 10^9/L$) since birth. During 3 years' old, the boy suffered from recurrent infection with thrombocytopenia ($81-174 \times 10^9/L$), red blood cells ($3.65-4.34 \times 10^9/L$), hemoglobin (110-126 g/L).

Cyclic neutropenia and hematologic disorders were found by bone marrow cytology. The peak for growth hormonestimulation test (insulin, arginine) was 6.55 ng/ml, 4.55 ng/ml, respectively. The bone age was 3.8 years (actual age 5.5 years) (Figure 1A). The predicted height was 166.6 ± 2.35 cm. The brain MRI scan was normal. The child was treated with rhGH solution (GenSci) at a dosage of 0.1IU/Kg-d. In the first year of the treatment, the child grew 12 cm and his bone age was 5.5 years (actual age 6.5 years), and his predicted height was $168.15+2.35$ cm (Figure 1B). During the second year, the child grew 7.5 cm and his bone age was 6.3 years (actual age 7.5 years), while his predicted height was $169.37+2.35$ cm (Figure 1C). At the age of 7.5 years, we obtained parental consent for the patient's genetic testing by Beijing Genomics Institute. And the known pathogenic mutation EX2 DEL of the SBDS gene and the likely pathogenic mutation c.258+2T>C were detected. Further verification by qPCR and Sanger sequencing confirmed that one mutation came from his father and the other one from his mother (Figure 2 and 3).

3. Discussion

Shwachman-Diamond syndrome (SDS) is a rare genetic disease. The SBDS gene (OMIM 607744) located on the proband is heterozygote of SBDS c.258+2T>C, this variant inherited from his mother (Figure 2). Three common SBD pathogenic or likely pathogenic mutation loci is located on 7q11.21, c.183-184delinsCT, c.258+2T>C, and c.[183-184delinsCT:258+2T]>C. Boocock GR found that about 90% of patients had at least one pathogenic variant and 62% had multiple variant [1]. In our patient, we detected the pathogenic variant exon2 deletion and the likely pathogenic variant c.258+2T>C through high throughput sequencing. Further verification by qPCR or Sanger sequencing confirmed that one variant came from his father and the other one from his mother.

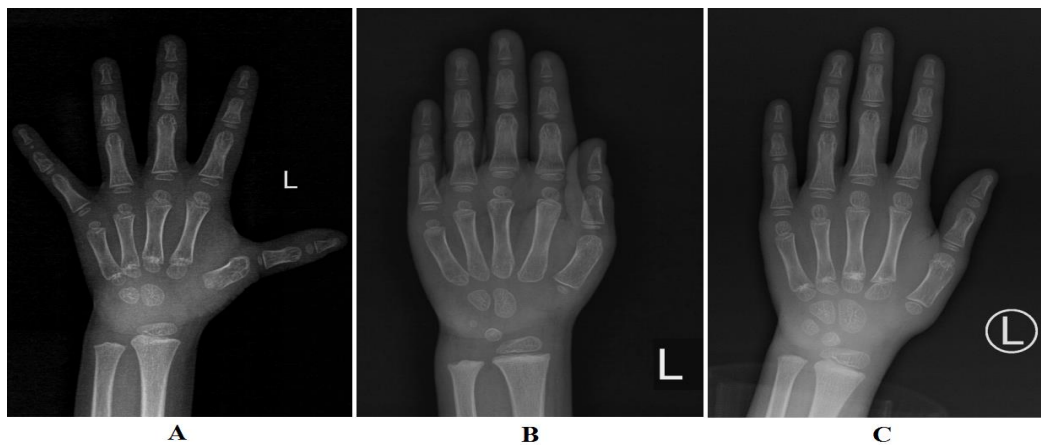


Figure 1: Improvement of bone age after GH treatment. A: The bone age was 3.8 years before GH treatment. The predicted height was 166.6 ± 2.35 cm; B: The bone age was 5.5 years after 12-months GH treatment. The predicted height was 168.15 ± 2.35 cm; C: The bone age was 6.3 years after 24-months GH treatment. The predicted height was 169.37 ± 2.35 cm.

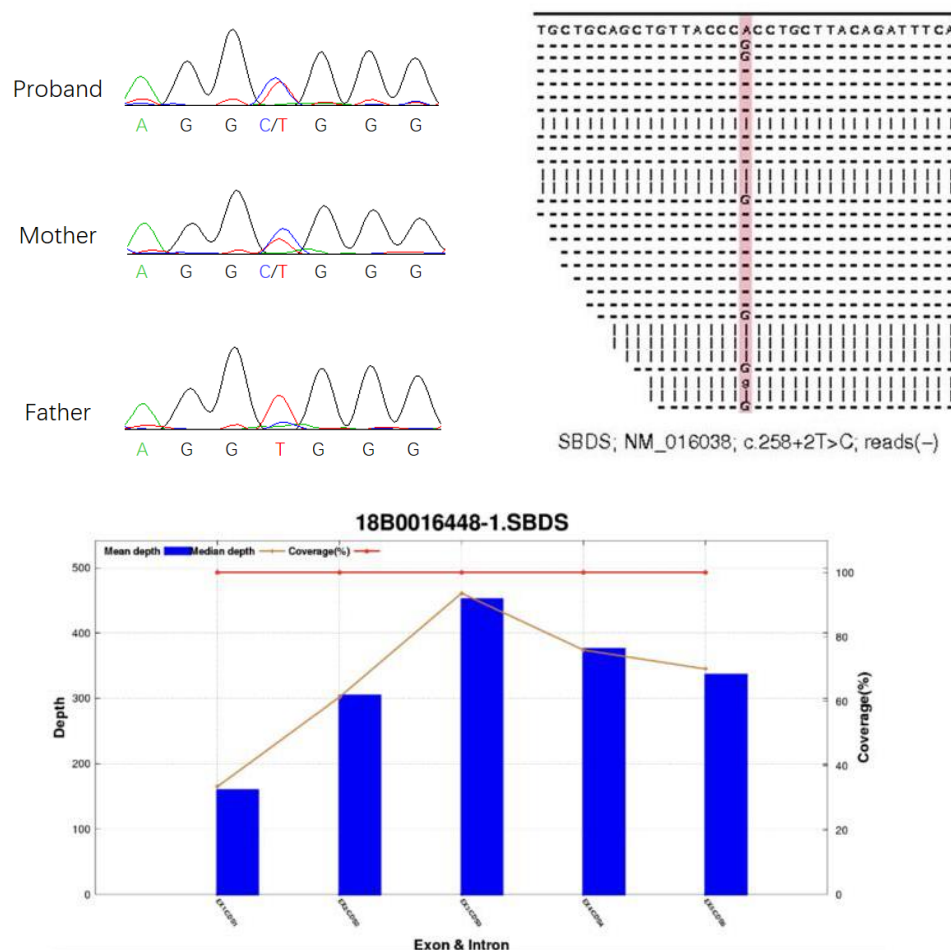


Figure 2: The proband is heterozygote of *SBDS* c.258+2T>C, this variant inherited from his mother.

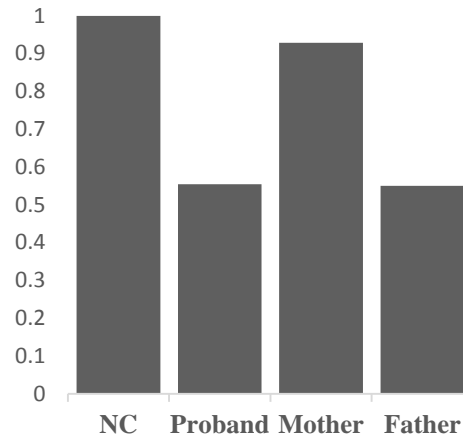


Figure 3: qPCR result of *SBDS* exon2 deletion. The proband is heterozygote of *SBDS* exon2 deletion, this variant inherited from his father. NC is short for normal control.

The main clinical symptoms of Shwachman-Diamond syndrome are pancreatic functional exocrine disorders, bone marrow failure, and one or more series of cytopenia [2-4]. Most patients have short stature, skeletal malformations, hepatic insufficiency, and severe infections [5, 6]. Persistent or intermittent reduction of neutrophils is the most common abnormal indicator of SDS in the blood system. Almost all patients have abnormalities in the blood system. The probability of granulocytic leukemia in SDS patients is 18%~36% [7]. Bone marrow cytology can help detect bone marrow diseases early, but the disease can change over time. Neutrophils are intermittently reduced in some patients. Growth retardation is another typical symptom of SDS. Some have reported that 38% of SDS patients are short, while stunted dysplasia is the cause of the short stature in 1/3 of patients. Myers reported that SDS patients also have growth hormone deficiency [8], which consistent with our patient. Therefore, SDS patients with short stature need to conduct endocrine tests such as a growth hormone stimulation test. However, Myers found that half of the 37 confirmed SDS patients had no typical clinical symptoms [8]. In our patient, the clinical symptoms of pancreatic exocrine disorders such as diarrhea are not obvious. The child got infected repeatedly in the neonatal period and gradually accompanied by neutropenia or lack of neutrophils and gradual thrombocytopenia. The pathogenic mutations were detected and the origin of the mutated gene was confirmed.

At present, there is no effective cure for SDS. For our young patient, granulocyte colony-stimulating factor is given when granulocytic deficiency is accompanied by severe infection. Blood tests should be conducted routinely and bone marrow cytology should be monitored. Currently, hematopoietic stem cell transplantation is reported to be the only effective method to treat bone marrow failure [9]. In addition, growth hormone therapy can have the benefits of SDS with short stature [10]. Based on the GH stimulation test results, the child was treated with rhGH, and the therapeutic effect is satisfactory.

SDS displays various clinical presentations and has a low incidence rate. Some clinicians lack the experience of dealing with this disease. The diagnosis of SDS for our patient is based on high throughput sequencing. Therefore,

for children with symptoms such as decreased or depleted neutrophils, progressive anemia, thrombocytopenia, repeated diarrhea, growth retardation, and skeletal dysplasia, it is necessary to conduct genetic testing early for clinical diagnosis.

Conflict of Interest

Authors declare to have no conflict of interest.

References

1. Boocock GR, Morrison JA, Popovic M. Mutations in SBDS are associated with Shwachman-Diamond syndrome. *J Nat Genet* 33 (2003): 97-101.
2. Cho WK, Jung IA, Kim J. Two cases of Shwachman-Diamond syndrome in adolescents confirmed by genetic analysis. *Ann Lab Med* 35 (2015): 269-271.
3. Donadieu J, Fenneteau O, Beaupain B. Classification of and risk factors for hematologic complications in a French national cohort of 102 patients with Shwachman-Diamond syndrome. *Haematologica J* 97 (2012): 1312-1319.
4. Myers KC, Davies SM, Shimamura A. Clinical and molecular pathophysiology of Shwachman-Diamond syndrome: an update. *Hematol Oncol ClinJ North Am* 27 (2013): 117-128.
5. Andolina JR, Morrison CB, Thompson AA. Shwachman-Diamond syndrome: diarrhea, no longer required? *Pediatr Hematol Oncol* 35 (2013): 486-489.
6. Grinspan ZM, Pikora CA. Infections in patients with Shwachman-Diamond syndrome. *Pediatr Infect Dis J* 24 (2005): 179-182.
7. Turlakis MEI, Zhong J, Gandhi R. Deficiency of Sbds in the Mouse Pancreas Leads to Features of Shwachman-Diamond syndrome. *With Loss of Zymogen Granules, Gastroenterology* 143 (2012): 481-492.
8. Myers Kc, Bolyard AA, Otto B. Variable clinical presentation of Shwachman-Diamond syndrome: update from the North American Shwachman-Diamond syndrome Registry. *J Pediatr* 164 (2014): 866-870.
9. Dror Y, Donadieu J, Kogelmeier J. Draft consensus guidelines for diagnosis and treatment of Shwachman-Diamond syndrome. *Ann N Y Acad Sci J* 1242 (2011): 40-55.
10. Myers KC, Rose SR, Rutter MM. Endocrine Evaluation of Children with and without Shwachman-Bodian-Diamond Syndrome Gene Mutations and Shwachman-Diamond Syndrome. *J Pediatr* 162 (2013): 1235-1240.

Citation: Li N, Zhang L, Yu XB, Zhu J, Liu ZJ. The Advantage of High Throughput Sequencing for the Diagnosis of Child Shwachman-Diamond Syndrome. *Archives of Clinical and Medical Case Reports* 3 (2019): 489-493.



This article is an open access article distributed under the terms and conditions of the [Creative Commons Attribution \(CC-BY\) license 4.0](https://creativecommons.org/licenses/by/4.0/)