

Case Report

Tension Pneumoperitoneum Following Diagnostic Colonoscopy Presenting as a Lethal Abdominal Compartment Syndrome

Sa'd Sayida^{1,2}, Kenan Hallon¹, Subhi Mansour¹, Safi Khuri^{1,3*}

¹General Surgery Department, Rambam Health Care campus, Haifa, Israel

²Advanced Laparoscopic and Bariatric Surgery Unit, Rambam Health Care Campus, Haifa, Israel

³HPB and Surgical Oncology Unit, Rambam Health Care Campus, Haifa, Israel

***Corresponding Author:** Dr. Safi Khuri, General Surgery Department, Rambam Health Care campus, Haifa, Israel;
E-mail: s_khuri@rambam.health.gov.il

Received: 08 July 2019; **Accepted:** 22 July 2019; **Published:** 24 September 2019

Abstract

Introduction: Nowadays, colonoscopy has become a very common procedure used to evaluate different colonic pathologies. Complications following this procedure are usually rare, with perforation being the most dreaded and severe one. An infrequent, yet potentially life-threatening complication of colonic perforation is abdominal compartment syndrome (ACS), due to continuous elevation of intra-abdominal pressure as a result of iatrogenic perforation.

Case Presentation: Herein, we report a case of a 73-year-old female patient, who presented to our Emergency Medicine department with abdominal pain and distension, hypotension and respiratory distress following diagnostic colonoscopy. An upright Chest x-ray revealed free air under the diaphragm, and the patient admitted with a diagnosis of abdominal compartment syndrome due to colonic perforation following diagnostic colonoscopy. On exploration of the abdomen, a 2 cm tear of the antero-medial wall of the cecum was demonstrated and an abbreviated laparotomy with right hemicolectomy and temporary closure of the abdomen was performed. Several hours following surgery, the patient developed multi-organ failure and died.

Conclusion: Abdominal compartment syndrome due to perforation after colonoscopy is an extremely rare condition, and a high index of suspicion is warranted for prompt early diagnosis and treatment.

Keywords: Abdominal compartment syndrome (ACS); Iatrogenic colon perforation

1. Introduction

Colonoscopy, introduced in the late 1960s, is a very common, safe and highly effective procedure used to examine the entire mucosa of the large bowel and rectum for variable pathologies [1, 2]. This exam is used for both diagnostic and treatment purposes, such as colonic polyps resection and for follow up of different colorectal diseases. Although considered safe, a colonoscopy does carry some risk with potentially serious complications. These complications include perforation, bleeding and post polypectomy syndrome, with perforation being the most feared one [3-5].

A colonoscopy is classified as diagnostic when the colon is examined for an abnormality in order to establish a diagnosis, or therapy, when abnormalities (often found during a screening) are treated. The incidence of perforation following a diagnostic colonoscopy ranges between 0.03–0.9%, and usually occur due to pressure effects on the colonic wall, especially in procedures that are classified as “difficult ” by endoscopists. Following therapeutic colonoscopy, perforation rates are higher, and range between 0.7%-2%. [3, 6]. Abdominal compartment syndrome occurs due to increased intra-abdominal pressure that results in organ failure. It may be due to several different causes, including acute pancreatitis, abdominal trauma, or severe burn and visceral edema following resuscitation. [7, 8]. Abdominal compartment syndrome due to perforation after diagnostic colonoscopy is an extremely rare entity [9, 10]. Herein, we describe a case of the lethal abdominal compartment syndrome due to perforation following diagnostic colonoscopy.

2. Case Presentation

A 73-year-old female patient, with a history of hypertension and diabetes mellitus, presented to our Emergency Medicine Department with abdominal pain and distension, shortness of breath and weakness two hours following diagnostic colonoscopy. She underwent a diagnostic colonoscopy at a private hospital due to positive fecal occult blood test. On physical examination upon her admission, the patient's vital signs showed tachycardia of 133/minute, a blood pressure of 100/70 mmHg, tachypnea of 32/minute, and an O₂ saturation of 86% along with a decreased level of consciousness. Abdominal examination revealed a very distended abdomen, cutis marmorata on the abdominal wall, and diffuse tenderness with guarding. No abdominal mass was palpated. Digital rectal exam was normal. Due to the severity of the abdominal pain and suspicion of abdominal catastrophe, endotracheal intubation and mechanical ventilation with 100% oxygen were carried out. Despite the previous maneuver, the patient's O₂ saturation did not improve, and her cyanosis and hemodynamic status worsened.

Complete blood count, liver and kidney function tests were within normal limits, with the exception of hypoglycemia, with glucose level of 29 mg/dl. Arterial blood gases revealed the following results: pH 7.16, lactate 9.4 mmol/L and base excess -8.00. An upright Chest X-ray showed free air under the diaphragm compressing the liver parenchyma (Figure 1). The patient was admitted with a diagnosis of post colonoscopy large bowel perforation with a suspicion of abdominal compartment syndrome, an hour following her arrival to our Emergency Medicine department. Due to the aforementioned diagnosis, an exploratory laparotomy was planned.

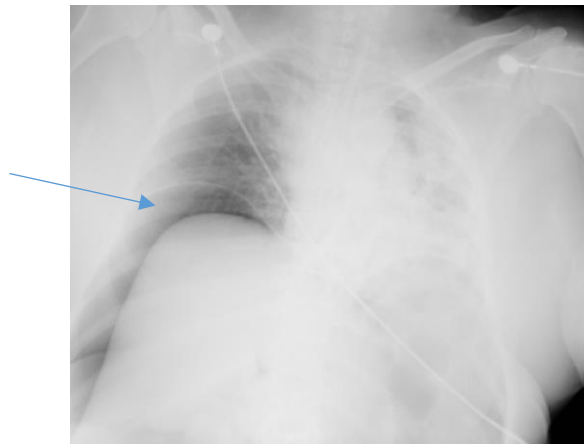


Figure 1: An upright chest X-ray demonstrates pneumoperitoneum (free air) under the left diaphragm (arrow), with pressure effect on the right liver lobe.

A few minutes before the surgical incision was made, the patient developed bradycardia that progressed to cardiac arrest. Cardiopulmonary resuscitation was immediately initiated, with a return of pulse and a blood pressure of 70/40 mm hg. Decompressive crush laparotomy was done, with the findings of a large amount of free air in the peritoneal cavity, a transmural tear of 2 cm at the antero-medial wall of the cecum (Figure 2) and a longitudinal serosal tear along the anterior wall of the ascending colon. An abbreviated laparotomy with right hemicolectomy and temporary closure of the abdomen was completed. Despite these efforts, the patient's vital signs and arterial blood gases did not improve. The patient was transferred to the Intensive Care Unit, hemodynamically unstable, for further management. Several hours following the surgery, despite maximal vasoactive treatment, the patient was in severe shock with multi-organ failure, and died 6 hours following admission.

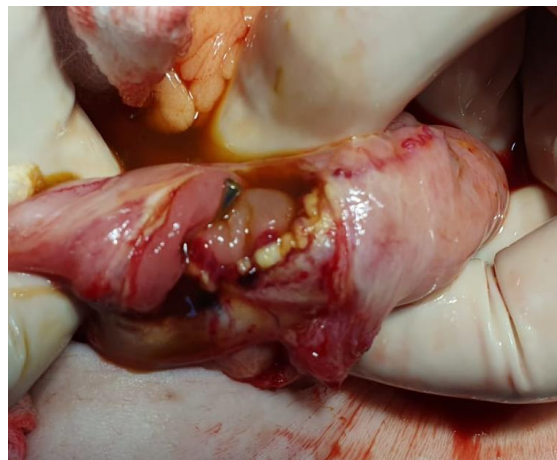

Figure 2: Intra-operative photo showing the transmural tear of the cecal wall.

3. Discussion

Recently, the indications for diagnostic and therapeutic colonoscopy have increased tremendously worldwide. This increment resulted in a parallel increase in the number of iatrogenic complications such as perforation and bleeding. Although rare, the incidence of perforation following diagnostic colonoscopy is approximately 0.9 out of 1,000 procedures, while it is far more common following therapeutic procedures [3, 6, 11]. Clinical presentation varies, and depends on several factors as perforation size, site, mechanism, underlying colonic pathology and peritoneal contamination degree [6].

Occasionally, perforations may be silent and, are therefore, not detected by the treating gastroenterologist. This may result in increased air insufflation, possibly leading to pneumoscotum, pneumothorax, pneumopericardium or pneumoperitoneum, which may evolve into tension pneumoperitoneum [4, 9, 12, 13]. Tension pneumoperitoneum may result in intra-abdominal hypertension, which in turn can develop into the abdominal compartment syndrome, when organ dysfunction occurs. According to the world society of abdominal compartment syndrome (ACS), ACS is defined as a sustained intra-abdominal pressure of more than 20 mmHg associated with organ failure. This entity may develop following diverse diseases, with abdominal surgery complicated by pre/post-operative bleeding, acute pancreatitis, abdominal trauma, retroperitoneal bleeding after aortic surgery and extended abdominal wall burns are the most common [14]. Recently, due to the increased use of laparoscopy surgeries, pneumoperitoneum has been added as a new potential cause for ACS [15]. The mainstay treatment for ACS, when suspected, is an immediate decompressive laparotomy.

ACS due to perforation following colonoscopy is a very rare entity and described as a few case reports in the English literature. Souadka et al. described a case of a patient with high rectal cancer who developed ACS with cardiac arrest following colonoscopy [16]. The patient was treated with needle decompression following the failure of cardiopulmonary resuscitation, with return of vital signs. Decompressive laparotomy with high anterior resection was done, and on follow up exam, the patient was doing well 3 years later. Chiapponi reported a retrospective analysis of pneumoperitoneum cases following iatrogenic bowel perforation [17]. Three patients, out of eleven, present with clinical sings of tension pneumoperitoneum and ACS, and treated immediately with percutaneous needle decompression, as a bridging maneuver, which improves hemodynamic conditions before operative intervention. All patients survived. This study demonstrated the importance of immediate treatment with needle decompression as a bridging maneuver to surgery, which was not done in our case.

4. Conclusion

Abdominal distension, along with hemodynamic and respiratory instability following colonoscopy, is highly suggestive of tension pneumoperitoneum and ACS. High index of suspection is always warranted for prompt early diagnosis and treatment. Bridging maneuver, as percutaneous needle decompression, is always advisable to relieve the tension pneumoperitoneum severity.

Acknowledgment

None

Conflict of Interest

None

Ethics Statement/Confirmation of Patient Permission

Ethics approval not required. Patient permission for publication was obtained.

References

1. Dafnis G, Ekblom A, Pahlman L, et al. Complications of diagnostic and therapeutic colonoscopy within a defined population in Sweden. *Gastrointest Endosc* 54 (2001): 302-309.
2. Wolff WI. Colonoscopy: history and development. *Am J Gastroenterol* 84 (1989): 1017-1025.
3. Castellví J, Pi F, Sueiras A, et al. Colonoscopic perforation: useful parameters for early diagnosis and conservative treatment. *Int J Colorectal Dis* 26 (2011):1183-1190.
4. Fernandes ML, Pires KC de C, Chimelli PHB, et al. Abdominal compartment syndrome during endoscopic clamping of an intestinal perforation secondary to colonoscopy. *Rev Bras Anesthesiol* 59 (2009): 614-617.
5. Putcha RV, Burdick JS. Management of iatrogenic perforation. *Gastroenterol Clin North Am* 32 (2003): 1289-1309.
6. Lohsiriwat V. Colonoscopic perforation: Incidence, risk factors, management and outcome. *World J Gastroenterol* 16 (2010): 425-430.
7. De Waele J, Desender L, De Laet I, et al. Abdominal decompression for abdominal compartment syndrome in critically ill patients: a retrospective study. *Acta Clin Belg* 65 (2010): 399-403.
8. Mentula P. Non-traumatic causes and the management of the open abdomen. *Minerva Chir* 66 (2011): 153-163.
9. Chiapponi C, Stocker U, Körner M, Ladurner R. Emergency percutaneous needle decompression for tension pneumoperitoneum. *BMC Gastroenterol* 11 (2011): 48.
10. Souadka A, Mohsine R, Ifrine L, et al. Acute abdominal compartment syndrome complicating a colonoscopic perforation: a case report. *J Med Case Reports* 6 (2012): 51.
11. Panteris V, Haringsma J, Kuipers EJ. Colonoscopy perforation rate, mechanisms and outcome: from diagnostic to therapeutic colonoscopy. *Endoscopy* 41 (2009): 941-951.
12. Ball CG, Kirkpatrick AW, Mackenzie S, et al. Tension pneumothorax secondary to colonic perforation during diagnostic colonoscopy: report of a case. *Surg Today* 36 (2006): 478-480.
13. Ignjatović M, Jović J. Tension pneumothorax, pneumoretroperitoneum, and subcutaneous emphysema after colonoscopic polypectomy: a case report and review of the literature. *Langenbecks Arch Surg* 394 (2009): 185-189.
14. Papavramidis TS, Marinis AD, Pliakos I, et al. Abdominal compartment syndrome-Intra-abdominal hypertension: Defining, diagnosing, and managing. *J Emerg Trauma Shock* 4 (2011): 279-291.

15. Papavramidis TS, Marinis AD, Pliakos I, et al. Abdominal compartment syndrome-Intra-abdominal hypertension: Defining, diagnosing, and managing. *J Emerg Trauma Shock* 4 (2011): 279-291.
16. Amine S, Raouf M, Lahsen I, et al. Acute abdominal compartment syndrome complicating a colonoscopic perforation: a case report. *Journal of Medical Case Reports* 6 (2012): 51.
17. Costanza C, Urban S, Markus K, et al. Emergency percutaneous needle decompression for tension pneumoperitoneum. *BMC Gastroenterology* 11 (2011): 48.

Citation: Sayida S, Hallon K, Mansour S, Khuri S. Tension Pneumoperitoneum Following Diagnostic Colonoscopy Presenting as a Lethal Abdominal Compartment Syndrome. *Archives of Clinical and Medical Case Reports* 3 (2019): 329-334.



This article is an open access article distributed under the terms and conditions of the [Creative Commons Attribution \(CC-BY\) license 4.0](https://creativecommons.org/licenses/by/4.0/)