

## Case Report

---

# Successful Endoscopic Management of Obstructive Jaundice in Von Hippel-Lindau Disease Caused by Multiple Pancreatic Serous Cystadenomas' Extrinsic Compression - A Case Report

Hunter Benvenuti MD<sup>1</sup>, Mandeep Singh MD<sup>2</sup>, Amir H Fathi MD, FACS<sup>1\*</sup>

<sup>1</sup>Department of Surgery, University of California San Francisco (UCSF), Fresno Medical Education program, Fresno, CA, USA

<sup>2</sup>Advanced Gastroenterology and Hepatology Associates, Fresno, CA, USA

**\*Corresponding Author:** Dr. Amir H Fathi, Assistant Clinical Professor of Surgery, Department of Surgery, University of California, San Francisco, Fresno Medical Education Program, 2335 E. Kashian Lane, Suite 220, Fresno, CA 93701, USA, Tel: 858-207-7064; E-mail: [afathi@fresno.ucsf.edu](mailto:afathi@fresno.ucsf.edu)

**Received:** 03 March 2020; **Accepted:** 16 March 2020; **Published:** 03 April 2020

## Abstract

Serous cystadenomas of the pancreas are a common entity in patients with von Hippel-Lindau (vHL) disease. However, to date, only thirteen cases of pancreatic cystic lesions causing obstructive jaundice in vHL patients have been reported in the literature, and these were the result of distal CBD stricture. In this study, we present a rare first case report of multiple large pancreatic serous cystadenomas causing obstructive jaundice via extrinsic compression of the mid CBD in a 27-year-old female with vHL. Biliary decompression has been successfully achieved with ERCP and stent placement, with serial stent exchanges every 2 months. Given the patient's young age and the morbidity associated with total pancreatectomy, we have elected to pursue a more conservative approach to her biliary obstruction via serial stent exchanges until they are no longer successful at achieving decompression, at which point we will proceed with surgical intervention such as biliary bypass or total pancreatectomy.

**Keywords:** Multiple Pancreatic Serous Cystadenomas; Pancreatic cystic lesions

## 1. Introduction

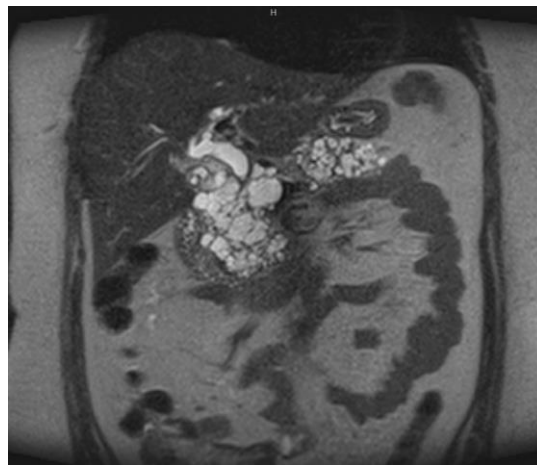
Von Hippel Lindau (vHL) disease is an autosomal dominant inherited disorder characterized by the mutation in the VHL gene, which results in the formation of multiple tumors and cysts throughout the body, notably the brain, kidneys, and pancreas. The range of manifestations of vHL disease is extensive. About 40 different lesions in 14 different organs have been described. These include retinal and central nervous system (CNS) hemangioblastomas,

endolymphatic sac tumors, renal cysts and tumors, pancreatic cysts and tumors, pheochromocytomas, and epididymal cystadenomas [1]. Over 70% of patients with vHL have a propensity to develop multiple pancreatic cysts<sup>2</sup>. Obstructive jaundice has been reported in association with vHL as a result of either extrinsic compression of the distal CBD or inflammatory stricture. Attempting conservative management for these cysts via biliary decompression with stents has been described as the standard of care, as these lesions have no malignant potential, and biliary bypass and total pancreatectomy carry considerable degrees of morbidity and mortality. Thus, here we present a case report of the conservative management of a mid CBD stricture due to extrinsic compression from large pancreatic serous cystadenomas in a patient with vHL.

## 2. Case Presentation

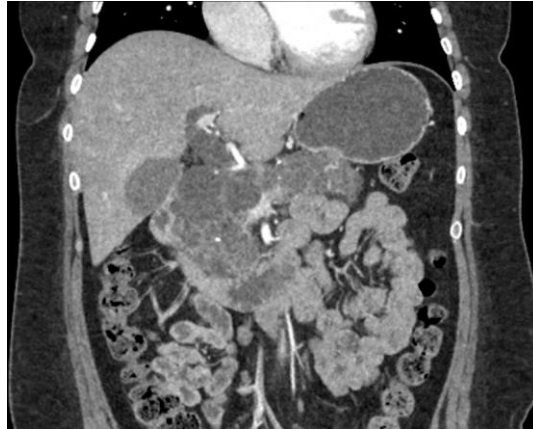
A 27-year-old female was referred to the HPB (Hepato- Pancreatico-Biliary) surgery service at our tertiary referral hospital, Community Regional Medical Center (CRMC) in Fresno, CA, for evaluation of symptomatic cholelithiasis. Subsequently, she was admitted with nausea, vomiting and oral intake intolerance. Detailed history and physical examination revealed, history of diabetes, obesity, depression and intermittent post-prandial nausea and vomiting, worse with greasy foods. On laboratory workup, she had a mild elevation in transaminases and mild leukocytosis, and normal total bilirubin and lipase. On US abdomen imaging, she had possible small gallstones, normal gallbladder wall, and CBD dilation to 12.9 mm. On HIDA imaging, she had decreased gallbladder ejection fraction of 15%, consistent with biliary dyskinesia.

Further work-up including abdominal imaging which revealed bilateral kidney masses. These masses were biopsied by interventional radiology, revealing bilateral renal cell carcinomas (RCC). Imaging also showed multiple pancreatic serous cystadenomas throughout the entire gland. The pattern of distribution was very suggestive of vHL disease (Figure 1). Laboratory work up including tumor markers to rule out pancreatic malignancies were all negative including Chromogranin A and CA 19-9. Renal biopsy samples were further analyzed by Foundation One CDx, next generation genomic sequencing (Foundation Medicine) revealing vHL disease. This finding prompted further testing including brain MRI which was negative for central nervous system (CNS) hemangioblastomas or endolymphatic sac tumors.



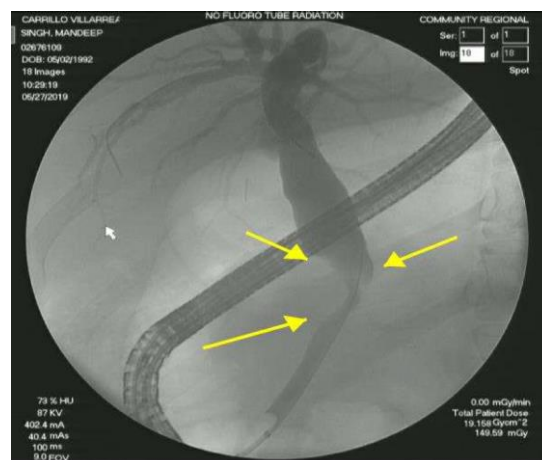
**Figure 1:** MRCP with biliary ductal dilatation and multiple pancreatic serous cystadenomas.

Based on her significant symptomatology, she underwent laparoscopic cholecystectomy with intraoperative ultrasound, revealing near-complete replacement of the pancreatic parenchyma with cysts. She tolerated the procedure well and was discharge home post-operatively. She is also status post robotic partial nephrectomy to address her RCCs.



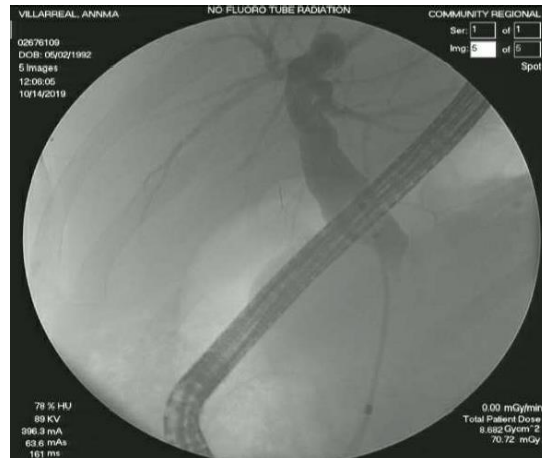**Figure 2:** CT scan with proximal CBD dilation due to mid CBD compression by large pancreatic cysts.

Four months later, she re-presented to CRMC for evaluation of obstructive jaundice. She complained of severe epigastric abdominal pain radiating to her back, as well as acholic stools. On laboratory workup, she had elevated transaminases and a total bilirubin of 2.4 (direct 1.7), with a normal lipase. On CT imaging, she was found to have a dilated proximal CBD to 16 mm likely due to extrinsic compression of a short-segment mid CBD by innumerable large pancreatic cysts (Figure 2). She underwent endoscopic retrograde cholangiopancreatography (ERCP) with sphincterotomy and 6-French plastic stent placement by GI. She tolerated the procedure well and was discharge home after normalization of her LFTs and resolution of symptoms (Figure 3).



**Figure 3:** Initial ERCP with stenting of mid CBD stricture.

Since that time, the patient has undergone serial ERCPs every 2 months, with removal and replacement of the temporary biliary stents. Her symptoms of biliary obstruction have resolved with this conservative management. However, the mid CBD stricture has persisted despite repeated stent placements (Figure 4).



**Figure 4:** 6-month follow up of ERCP with stent exchange.

### 3. Discussion

Cystic lesions of the pancreas carry no malignant potential in vHL, and as a result, these patients do not require operative resection unless they develop biliary obstructive symptoms that cannot be managed via endoscopic stent placement [2, 3]. While there have only been thirteen cases of obstructive jaundice developing in vHL patients as a result of extrinsic distal biliary compression by pancreatic cysts, to date, this is the first report of mid biliary compression by pancreatic cysts [4-10].

This patient serves as a successful example of management of biliary obstruction in vHL disease by endoscopic decompression, sphincterotomy and stent placement with serial stent exchanges. This approach is especially beneficial in younger patients, as the morbidity and mortality associated with surgical biliary bypass or total pancreatectomy have the potential to severely limit the longevity and quality of life in these populations [11]. Furthermore, given the advances in endoscopic interventions as well as surveillance modalities for potential malignancy, conservative management in these cases constitutes a safe and effective plan of care. Thus, we present a rare case report of multiple serous cystadenomas of the pancreas causing mid CBD obstruction with jaundice in a vHL patient, which has been successfully managed with endoscopic decompression with stenting.

### Conflict of Interest Statement

Authors do not have any conflict of interest “None Declared” in this research.

### Author Contribution Statement

All authors contributed to the conception, design, or data analysis of this work; contributed to drafting or critical revision of the intellectual content of this work; and give final approval of the version to be published. All authors agree to be accountable for this work.

### References

1. Melmon KL, Rosen SW. Lindau's Disease. Review of the Literature and Study of a Large Kindred. Am J Med 36 (1964): 595-617.
2. Hammel PR, Vilgrain V, Terris B, et al. Pancreatic involvement in von Hippel-Lindau disease. The Groupe Francophone d'Etude de la Maladie de von Hippel-Lindau. Gastroenterol 119 (2000): 1087-1095.
3. Charlesworth M, Verbeke CS, Falk GA, et al. Pancreatic lesions in von Hippel-Lindau disease? A systematic review and meta-synthesis of the literature. J Gastrointest Surg 16 (2012): 1422-1428.
4. Beerman MH, Fromkes JJ, Carey LC, et al. Pancreatic cystadenoma in Von Hippel-Lindau disease: an unusual cause of pancreatic and common bile duct obstruction. J Clin Gastroenterol 4 (1982): 537-540.
5. Boujaoude J, Samaha E, Honein K, et al. A benign cause of obstructive jaundice with von Hippel-Lindau disease. A case report and review of the literature. JOP 8 (2007): 790-794.
6. Cheng TY, Su CH, Shyr YM, et al. Management of pancreatic lesions in von Hippel-Lindau disease. World J Surg 21 (1997): 307-312.
7. Deboever G, Dewulf P, Maertens J. Common bile duct obstruction due to pancreatic involvement in the von Hippel-Lindau syndrome. Am J Gastroenterol 87 (1992): 1866-1868.
8. Fellows IW, Leach IH, Smith PG, et al. Carcinoid tumour of the common bile duct--a novel complication of von Hippel-Lindau syndrome. Gut 31 (1990): 728-729.
9. Gallego Sanchez JA, Pereira Arias JG, Larrinaga Simon J, et al. Renal carcinoma and von Hippel-Lindau disease. Actas Urol Esp 22 (1998): 428-430.
10. Issar SK, Kumar N, Sachdeva AK, et al. von Hippel Lindau syndrome presenting as obstructive jaundice with involvement of pancreas in two siblings. T Trop Gastroenterol 17 (1996): 30-32.
11. Zakaria HM, Stauffer JA, Massimo R, et al. Total pancreatectomy: Short- and long-term outcomes at a high-volume pancreas center. World J Gastrointest Surg 8 (2016): 634-642.

**Citation:** Hunter Benvenuti, Mandeep Singh, Amir H Fathi. Successful Endoscopic Management of Obstructive Jaundice in Von Hippel-Lindau Disease Caused by Multiple Pancreatic Serous Cystadenomas' Extrinsic Compression - A Case Report. Archives of Clinical and Medical Case Reports 4 (2020): 280-284.



This article is an open access article distributed under the terms and conditions of the [Creative Commons Attribution \(CC-BY\) license 4.0](https://creativecommons.org/licenses/by/4.0/)