

## Case Report

# Subacute Constrictive Pericarditis after mRNA Covid-19 Vaccination

Iilir Hysi<sup>1\*</sup>, Olivier Rebet<sup>1</sup>, Bruno Vaquette<sup>2</sup>, Olivier Fabre<sup>1</sup>

<sup>1</sup>Departement of Cardiac Surgery of Artois, Centre Hospitalier de Lens et Hôpital privé de Bois Bernard, Ramsay Santé, France

<sup>2</sup>Departement of Cardiology, Hôpital privé de Bois Bernard, Ramsay Santé, France

**\*Corresponding Author:** Iilir Hysi, Departement of Cardiac Surgery of Artois, Centre Hospitalier de Lens et Hôpital privé de Bois Bernard, Ramsay Santé, France.

**Received:** 23 February 2022; **Accepted:** 04 March 2022; **Published:** 09 March 2022

**Citation:** Iilir Hysi, Olivier Rebet, Bruno Vaquette, Olivier Fabre. Subacute Constrictive Pericarditis after mRNA Covid-19 Vaccination. Archives of Clinical and Medical Case Reports 6 (2022): 189-192.

### Abstract

Relation between mRNA Covid-19 vaccine and acute pericarditis has been advocated. However, we have with no further information about the mid-term evolution of this complication. Here we present the possibility of a rapid evolution towards a constrictive pericarditis. Physicians should know this possibility and closely follow-up these patients.

**Keywords:** Covid-19; Acute pericarditis; mRNA Covid-19 vaccines; Myocarditis

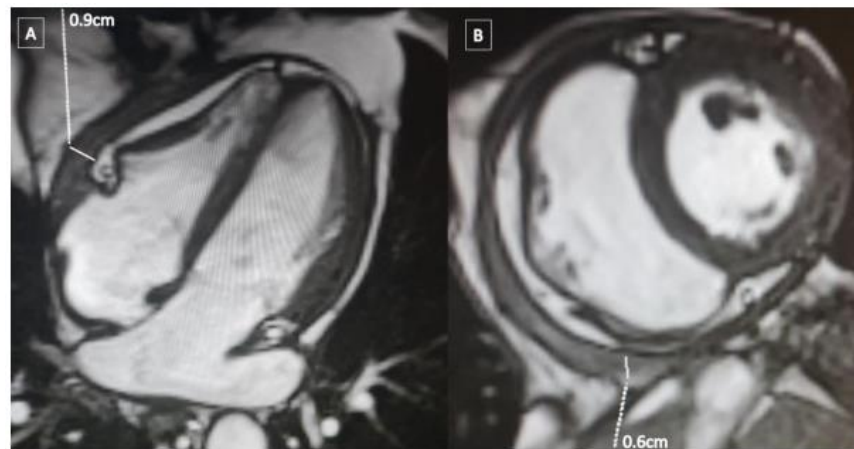
### 1. Background

During the recent Covid-19 pandemic, while vaccination rates are growing worldwide, there has been debate about potential cardiac manifestations of the anti-Covid-19 vaccination and the viral infection itself. Although recent studies have demonstrated the safety of the mRNA Covid-19 vaccines [1], some authors have evoked the possibility of rare acute myocarditis/pericarditis following vaccines [2]. Here we describe for the first time the case of a rapidly evolving constrictive pericarditis after a mRNA Covid-19 Pfizer vaccination.

## 2. Case Study

The patient was a 63-year-old man with a past medical history of peripheral arterial disease and pulmonary embolism in 2019. He had been receiving rivaroxaban (Xarelto) 20mg daily for two years. He was inoculated the first dose of the BNT162b2 Pfizer BioNTech vaccine on April 21st and three days later he reported to the cardiology department, resenting with shortness of breath. Transthoracic echocardiography showed a moderate pericardial effusion without signs of compression. Troponin assays were within normal range which was taken as evidence against myocarditis. A diagnosis isolated pericarditis was made and the patient was treated by oral nonsteroid anti-inflammatory drugs (Ibuprofen) and colchicine. On the May 25th the patient returned to the hospital with symptoms of tamponade. Echocardiography

showed increased pericardial effusion with compression on the right chambers. The patient was transferred to the operating room where a pericardial drainage was performed through a subxiphoid incision (150ml of hemorrhagic liquid). He was discharged home three days later in stable clinical condition. The anti-inflammatory drugs were discontinued after one month of treatment. His second dose of the same vaccine of June 7th were not followed by any clinical problem. The patient presented again at the hospital in August, with a severe shortness of breath and lower limb swelling. A thickened pericardium with signs of constriction of the right side of the heart but no signs of pericardial effusion were on ultrasound. These findings were confirmed by the magnetic resonance imaging (Figure 1).



**Figure 1:** Magnetic resonance imaging of the heart. **A)** Axial view showing a thickening of the pericardium on the anterior part of the right ventricle. **B)** Coronal view showing a semicircular thickening of the pericardium constricting the right ventricle.

Left heart catheterization was normal and right heart catheterization did not show a dip plateau sign. The patient was referred for surgical constrictive pericarditis in order to relieve constriction on September 21st of the same year. During the procedure, the pericardium was hardened and showing obvious signs of inflammation. The surgery liberated the heart after an extended pericardiectomy, without the need for cardiopulmonary bypass. The patient's clinical condition improved immediately after the surgery and the postoperative period was uneventful. Cytologic examination of the pericardium showed nonspecific inflammatory infiltration. Currently the patient reports being in good health and absence of any symptoms.

### 3. Discussion

Constrictive pericarditis is a rare but well-known heart disease that often requires cardiac surgery. It ensues any inflammatory process involving the pericardium. In industrialized countries the most common causes are idiopathic or viral, or following surgical, radiation, and inflammatory or infectious disease, while tuberculosis remain a major cause in developing countries [3]. To our knowledge, there have been only three published cases of related constrictive pericarditis in the presence of exposure to Covid-19 [3-5]. In two of these cases the patients died due to the catastrophic evolution of their pulmonary Covid-19 lesions and the third patient survived on a treatment consisting of pericardiocentesis combined with oral anti-inflammatory therapy. On the other hand, there has been concerns about the safety of Covid-19 mRNA vaccines. The European Medicines Agency reports a combined incidence rate of myocarditis and pericarditis in the order of 1.6 per million among the recipients of the 160 million doses administered [2]. Importantly myocarditis outnumbers pericarditis by 3:2. To our knowledge, there has been no

description in the literature of cases of constrictive pericarditis following inoculation mRNA vaccination. Our patient experienced an initial pericardial effusion a few days after the first dose of the vaccine. Although causality cannot be established with absolute certainty, an adverse effect of the vaccine may reasonably be among the possible causes. Although anti-inflammatory oral treatment and pericardiocentesis were promptly administered, the condition rapidly deteriorated towards rapid pericarditis with three months of the onset of symptoms. There may be open questions on whether a prolonged course of initial anti-inflammatory treatment, in the space of three to six months could have avoid the secondary inflammatory infiltration and thickening of the pericardium. This case illustrates the extremely rare, but real possibility of constrictive pericarditis after mRNA anti Covid-19 vaccination. Intense follow-up of similar patients may be of particular importance, especially given that the use of these vaccines is likely to increase across the world in response to a developing pandemic.

### Conflict of Interest

None to declare

### Funding Statement

No funding received for this work.

### References

1. Barda N, Dagan N, Ben-Shlomo Y, et al. Safety of the BNT162b2 mRNA Covid-19 Vaccine in a Nationwide Setting. *N Engl J Med* 385 (2021): 1078-1090.
2. Pepe S, Gregory AT, Denniss AR. Myocarditis, Pericarditis and Cardiomyopathy After COVID-19 Vaccination. *Heart Lung Circ* 30 (2021):1425-1429.

3. Beckerman JK, Alarfaj M, Tracy CM, et al. Coronavirus disease 2019 (COVID-19)-associated constrictive pericarditis. *BMJ Case Rep* 14 (2021): 242018.
4. Diaconu R, Popescu L, Voicu A, et al. Subacute effusive-constrictive pericarditis in a patient with COVID-19. *BMJ Case Rep* 14 (2021): 242443.
5. SeyedAlinaghi S, Ghadimi M, Gharabaghi MA, et al. Constrictive Pericarditis Associated with Coronavirus Disease 2019 (COVID-19): A Case Report. *Infect Disord Drug Targets* 21 (2021): 160921188928.



This article is an open access article distributed under the terms and conditions of the [Creative Commons Attribution \(CC-BY\) license 4.0](https://creativecommons.org/licenses/by/4.0/)