

## Pediatric Acute Respiratory Distress Syndrome and Sepsis in Children with Dravet Syndrome Following Upper Respiratory Tract Infections

Friederike Schwarz<sup>1\*</sup>, Gabriela Oesch<sup>2</sup>, Christoph Aebi<sup>3</sup>, Elisabeth Kieninger<sup>4</sup>, Thomas Riedel<sup>1</sup>

### Abstract

Herein we report on four children with *SCN1A* related Dravet syndrome (DS) with severe pediatric acute respiratory distress syndrome (PARDS) and sepsis following upper respiratory infections that have occurred in clusters over a short period of time. Complications included PARDS with need of veno-venous extracorporeal membrane oxygenation (VV-ECMO) and acute kidney injury treated with continuous veno-venous hemodiafiltration (CVVHDF). This striking observations warrant further exploration of DS patients' susceptibility to respiratory tract infections.

**Keywords:** Dravet syndrome; *SCN1A* mutation; Respiratory infections; PARDS; Sepsis; Multi-organ failure.

### Introduction

Severe complications of pulmonary infections in patients with DS have been reported previously [1 - 4], however, might be still underestimated in the pediatric patients [3]. Only a few studies reported on the role of specific pathogens [1, 2], however, the exact pathophysiologic mechanisms of the severe reaction to simple upper respiratory infections in DS patients still need to be clarified [1, 4]. The impact of respiratory infections on morbidity and outcome in children with DS due to *SCN1A* mutation will be highlighted in the following case series.

### Case Series

Four patients aged 5.5 years (median, range 1.5 - 13.7) with *SCN1A* related Dravet syndrome were admitted to the PICU of the Bern University Hospital between February and May 2023: three of them presented with rapid respiratory deterioration due to pediatric acute respiratory distress syndrome (PARDS) and one with sepsis secondary to pleuropneumonia (table 1). Pathogens identified included Influenza type B and enterovirus. All of the children had upper respiratory tract infections in the weeks prior to admission. Two of the ARDS patients required one VV-ECMO run for 5 and 11 days, respectively (Figure 1). Oxygenation index was > 25 in all ARDS patients (median 67, range 29 - 68) and mechanical ventilation was needed for 14 days (median, range 5 - 16). All patients were under inotropic support for median 4 days (range 3 - 6). One of the ECMO patients was treated with CVVHDF for acute kidney injury for 10 days. Renal function normalized after ECMO weaning. Short seizures were witnessed in two patients, EEG ruled out status epilepticus. Neuroimaging (cerebral MRI or CT) was performed in three patients excluding bleeding and ischemia. The already before admission

### Affiliation:

<sup>1</sup>Department of Paediatrics, Division of Paediatric Intensive Care Medicine, Inselspital, Bern University Hospital, University of Bern, Switzerland

<sup>2</sup>Department of Paediatrics, Division of Neuropaediatrics, Development and Rehabilitation, Inselspital, Bern University Hospital, University of Bern, Switzerland

<sup>3</sup>Department of Paediatrics, Division of Paediatric Infectious Diseases, Inselspital, Bern University Hospital, University of Bern, Switzerland

<sup>4</sup>Department of Paediatrics, Division of Paediatric Respiratory Medicine and Allergology, Inselspital, Bern University Hospital, University of Bern, Switzerland

### \*Corresponding Author

Friederike Schwarz, Department of Paediatrics, Division of Paediatric Intensive Care Medicine, Inselspital, Bern University Hospital, University of Bern, Switzerland

**Citation:** Friederike Schwarz, Gabriela Oesch, Christoph Aebi, Elisabeth Kieninger, Thomas Riedel. Pediatric Acute Respiratory Distress Syndrome and Sepsis in Children with Dravet Syndrome Following Upper Respiratory Tract Infections. Archives of Clinical and Medical Case Reports. 8 (2024): 23-25.

**Received:** January 12, 2024

**Accepted:** January 22, 2024

**Published:** February 13, 2024

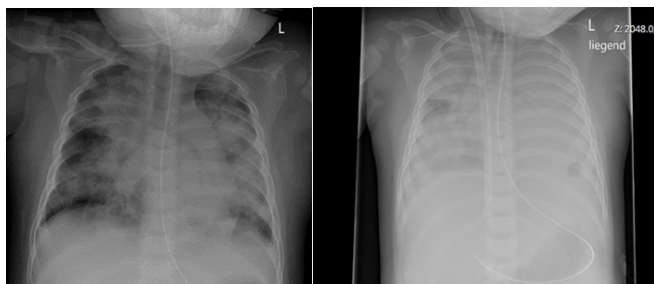
installed antiepileptic combination therapy was continued. Antibiotic agents were given for 13 days (median, range 6 – 16 days), blood cultures remained negative in all patients. Thrombocytopenia was present in all patients, two patients were pancytopenic. Length of stay at PICU was 15 days (median, range 6 – 26 days), length of hospital stay 24 days

(median, range 11 – 35). None of the patients died. Recovery from the acute illness was heterogenic and required weeks to months. At time of discharge all patients showed increased muscular weakness and fatigue compared to their baseline before hospitalization; one of the ECMO patients suffered from critical illness myopathy.

**Table 1:** Patients' characteristics

Patient	1	2	3	4
Age	1 y 8 mo	1 y 6 mo	9 y 6 mo	13 y 8 mo
Sex	m	m	m	f
Antiepileptic medication	valporic acid, stiripentol, clobazam	valporic acid, stiripentol, clobazam	valporic acid, clobazam, topiramate	valporic acid, stiripentol, clobazam, topiramate
Main diagnosis of hospital stay	Sepsis	PARDS	PARDS	PARDS
Duration of illness before ICU admission (d)	8	5	6	4
Length of stay, PICU (d)	6	21	9	26
Length of stay, hospital (d)	20	28	11	35
Mechanical ventilation (d)	-	16	5	14
VV-ECMO (d)	-	11	-	5
CVVHDF (d)	-	10	-	-
Inotrops (d)	4	3	3	6
Length of antibiotic treatment (d)	10	16	6	16
Transfusion of RBC / TC	- / +	+ / +	- / -	+ / +
pSOFA score at PICU admission	12	14	16	14
Oxygenation index at PICU admission	-	68	29	67
CRP (max., g/l)	121	240	43	390
Pathogenes identified: acute (weeks before admission)	Enterovirus	- (Picornavirus, parainfluenza virus)	Influenza type B	Candida albicans (EBV)

ARDS = acute respiratory distress syndrome; CVVHDF = continuous veno-venous hemodiafiltration; d = days; EBV = Epstein Barr virus; f = female; m = male; mo = months; PICU = pediatric intensive care unit; pSOFA score = pediatric sequential organ failure assessment score; RBC = red blood cells; TC = thrombocytes; VV-ECMO = veno-venous extracorporeal membrane oxygenation; y = years



**Figure 1:** Chest X-ray at admission to PICU with signs of severe PARDS (left side) and X-ray after jugular VV-ECMO cannulation via dual-lumen cannula (right side) of the same patient following rapid respiratory deterioration few hours later.

## Discussion

Few studies report the impact of respiratory tract infections in patients with DS [1, 2]. Howell et al demonstrated the neurologic complications and sequelae caused by Influenza infections in 24 patients [1]. Clinical findings were similar to those in our patients, including pneumonia, ARDS and acute kidney injury. They reported one death (4.2%), caused by pneumonia. Bjurulf et al found a mortality rate of respiratory infections as high as 5.7% (3/53 children) in pediatric DS patients [3]. The survey of Balestrini et al regarding the impact of COVID-19 infection on the DS population in the UK showed a good outcome and low infection rate due to

early prevention measures [2]. Takastuki et al reported a case of a girl with deletion 2q24.2 including the *SCN1A* mutation with severe pulmonary emphysema secondary to pneumonia [4]. They suspected the pulmonary complication to be caused by the loss of the integrin  $\beta 6$  gene (ITGB6).

Until now there is no clear understanding of the underlying pathophysiology in DS with respiratory infections and severe clinical course leading to PARDS. In our case series we demonstrate four cases of severe multi-organ dysfunction following respiratory infections in children with *SCN1A* related Dravet syndrome. Patients suffered life-threatening complications including respiratory and kidney failure as well as long-term neurologic sequelae. We were surprised by the rapid progression and the severity of the patients' course (figure 1). Pathogens were identified in two of the patients, differed from patient to patient (Influenza type B, enterovirus) and were not age-dependent. It is likely that DS patients' pulmonary vulnerability is not limited to a special pathogen or age-group but might be more likely related to its underlying genetic constellation. The gene *SCN1A* is primarily expressed in the brain and also in the lungs, thus might play a crucial role in pathogenesis of severe pulmonary disease [5].

## Conclusion

The striking observations of PARDS and sepsis in Dravet patients warrants further exploration of DS patients' susceptibility to respiratory tract infections. Due

to the potential of rapid clinical deterioration we strongly recommend treating DS patients with caution when identifying respiratory infection, such as early antibiotic treatment and PICU consultation.

## Acknowledgements and Funding

Not applicable.

## Conflicts of Interests

The authors of this article have no conflicts of interest.

## References

1. Howell KB, Butcher S, Schneider AL, Russ-Hall S, Muzariri PR, et al. Complications of Influenza A or B Virus Infection in Individuals With *SCN1A*-Positive Dravet Syndrome. *Neurology* 100 (2023): e435-e442.
2. Balestrini S, Wilson G, Eldred C, Evans H, Sisodiya SM. The impact of COVID-19 in Dravet syndrome: A UK survey. *Acta Neurol Scand* 143 (2021): 389-395.
3. Bjurulf B, Reilly C, Sigurdsson GV, Thunström S, Kolbjørn S, et al. Dravet syndrome in children-A population-based study. *Epilepsy Res* 182 (2022): 106922.
4. Takastuki S, Nakamura R, Haga Y, Mitsui K, Hashimoto T, et al. Severe pulmonary emphysema in a girl with interstitial deletion of 2q24.2q24.3 including *ITGB6*. *Am J Med Genet Part A* 152 (2010): 1020-1025.
5. The Human Protein Atlas (2023).