

Case Report

Lumbar Intradural Extramedullary Isolated Hemangioblastoma: A Rare Entity and Review of Literature

Muhammad Mohsin Khan^{1*}, Kazim Mohammed², Javeed Iqbal², Surya Batas¹, Khaled Al-sawalmeh³, Issam Al Bozom³, Ali Raza⁴

¹Resident neurosurgery, Hamad Medical Corporation, Doha, Qatar

²Specialist neurosurgery, Hamad Medical Corporation, Doha, Qatar

³Department of pathology, Hamad Medical Corporation, Doha, Qatar

⁴Senior consultant neurosurgery, Hamad Medical Corporation, Doha, Qatar

***Corresponding Author:** Muhammad Mohsin Khan, Resident neurosurgery, Hamad Medical Corporation, Doha, Qatar, E-mail: mkhan51@hamad.qa

Received: 03 May 2020; **Accepted:** 16 May 2020; **Published:** 04 June 2020

Citation: Muhammad Mohsin Khan, Kazim Mohammed, Javeed Iqbal, Surya Batas, Khaled Al-sawalmeh, Issam Al Bozom, Ali Raza. Lumbar Intradural Extramedullary Isolated Hemangioblastoma: A Rare Entity and Review of Literature. Journal of Spine Research and Surgery 2 (2020): 077-084.

Abstract

The terminology “Intradural Extramedullary” is often associated with Nerve sheath tumors (schwannoma, Neurofibroma) and Meningioma, while dermoid cyst, epidermoid, neurenteric cyst are other benign entities. Hemangioblastomas are rare, accounting for 1-5% of all spinal cord tumours.¹ 75% of the Spinal hemangioblastoma are Intramedullary, and another 10-15% have combined intramedullary and extramedullary-intradural component, while isolated extramedullary hemangioblastoma are rare¹. Our case had an isolated intradural extramedullary hemangioblastoma without

any associated manifestations of VHL syndrome. Surgery is a preferred option where total resection is possible, where as SRS is also an option in case of residual or incomplete resection.

Keywords: Intradural Extramedullary; Hemangioblastoma; VHL syndrome; MRI

1. Case Report

33 years old female, no chronic medical condition, presented to emergency department with the complaints

of low back pain radiating to right lower limb for the past 3 months with exacerbation of symptoms since 2 weeks, necessitating repeated visits to ED. She also complained of urinary retention and weak urine stream for one day prior to presentation.

1.1 Examination on admission

Patient seemed to be in distress because of pain. Power in both limbs was grossly 4+/5, numbness both LL, saddle anesthesia, lax anal tone. Deep tendon reflexes seemed to be normal. An urgent MRI revealed an Intradural mass at L3-L4 vertebral level with intense enhancement labelled by radiologist as meningioma.

1.2 Operation

The tumor was exposed by L3 total and L4 partial

Laminectomy. The tumor was well circumscribed, highly Vascular. Multiple blood vessels were covering the tumor.

Complete excision of intradural extramedullary lesion was achieved by microsdissection. The patient's recovery was uncomplicated. Post operatively she received active Physio and rehabilitation. Patient did not have any neuro deficit at discharge.

1.3 Follow up

Followed in OPD at 4 months. No neurological deficits. Screening MRI of brain and whole spine showed no evidence of any associated lesion. Other screening for VHL came out to be negative.

PRE-OP MRI :

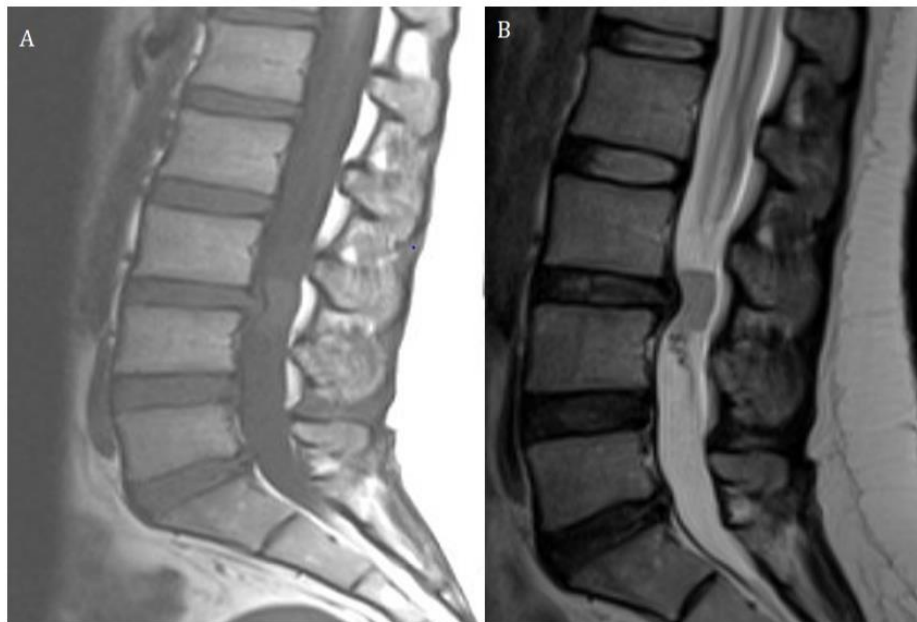


Figure 1: A and B. A well-defined intradural mass is seen at L3-L4 disk level. It appears isointense to the spinal cord on T1WI and T2WI.

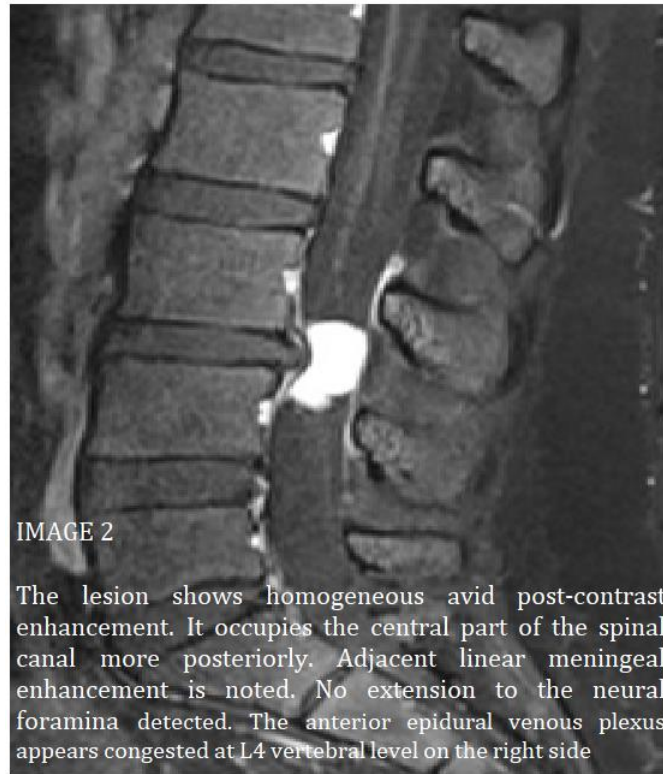

Figure 2: The lesion shows homogeneous avid post-contrast enhancement. It occupies the central part of the spinal canal more posteriorly. Adjacent linear meningeal enhancement is noted. No extension to the neural foramina detected. The anterior epidural venous plexus appears congested at L4 vertebral level on the right side.

POST-OP MRI:

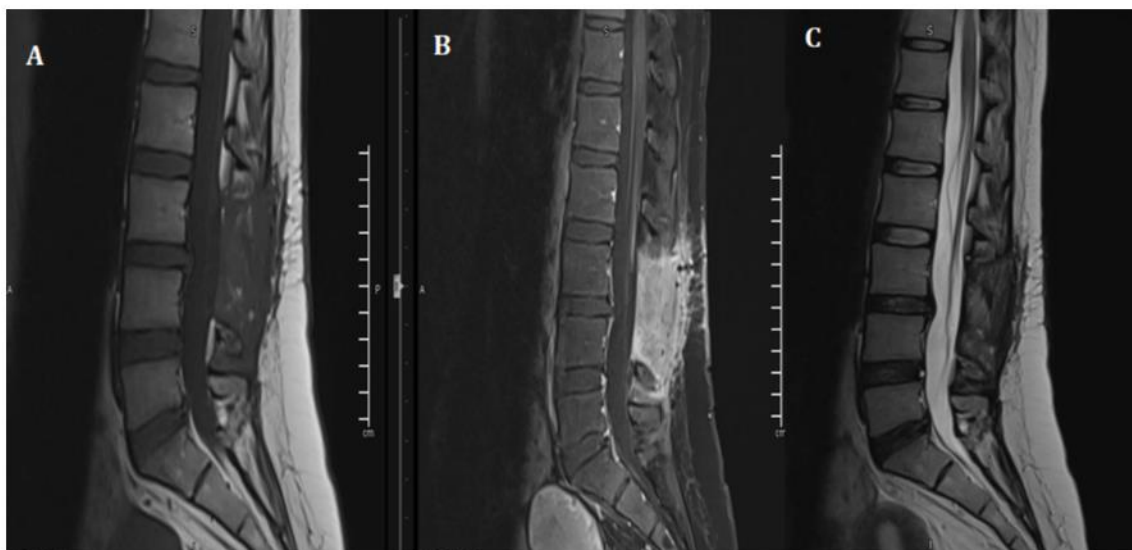


Figure 3: POST –OP follow up MRI shows total resection of the Lesion.

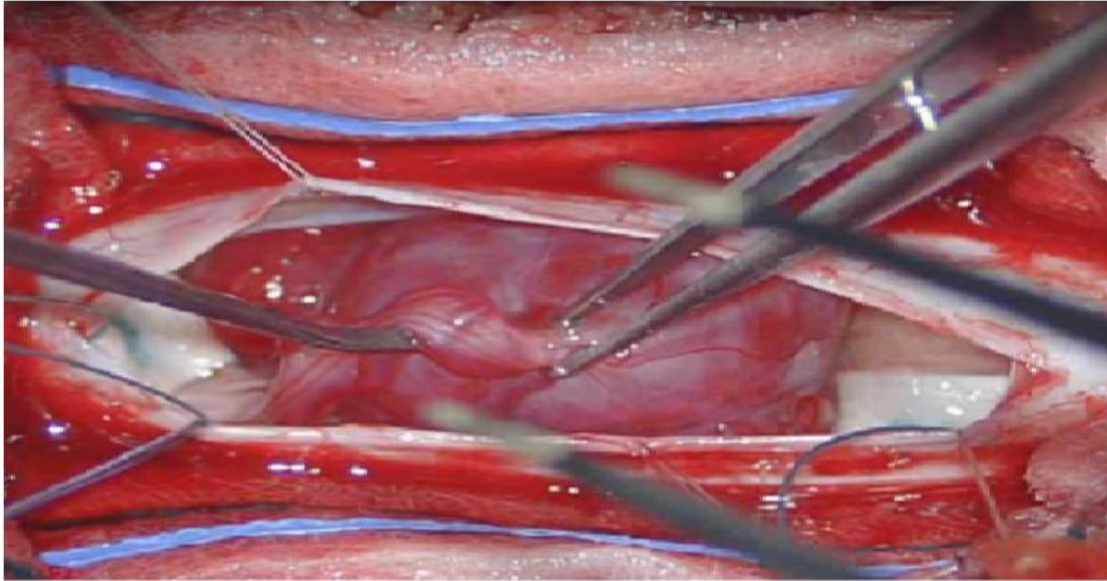


Figure 4: Intra-operative images Showing a solitary well capsulated Red colored Lesion with surrounding vessels and attached to Nerve root.

1.4 Pathology slides

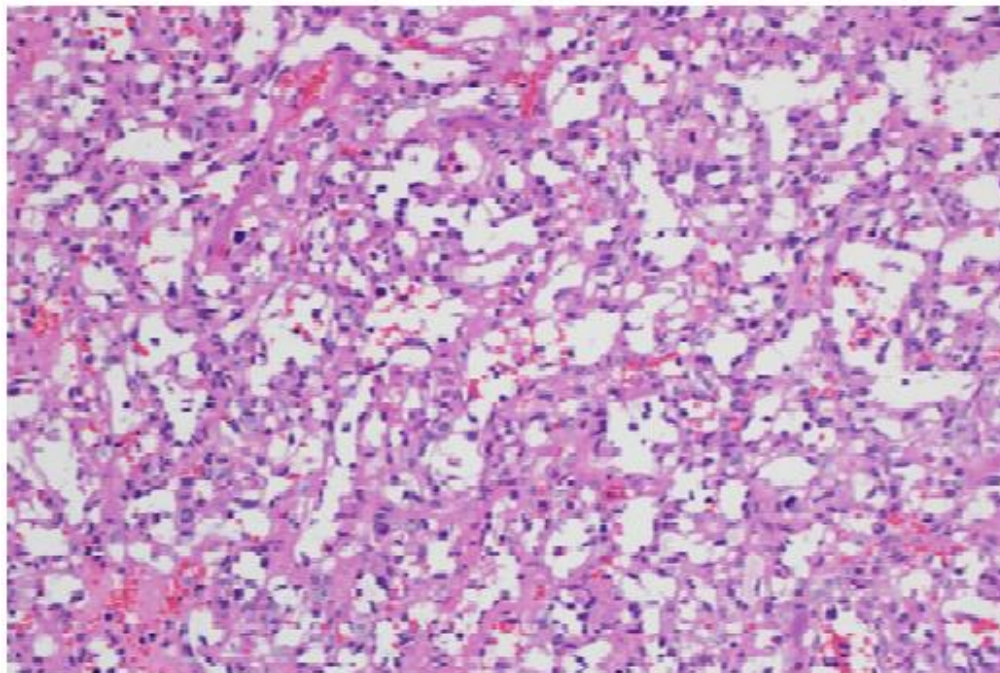


Figure 5: Light microscopic view showing richly vascular tumor (H&E X200).

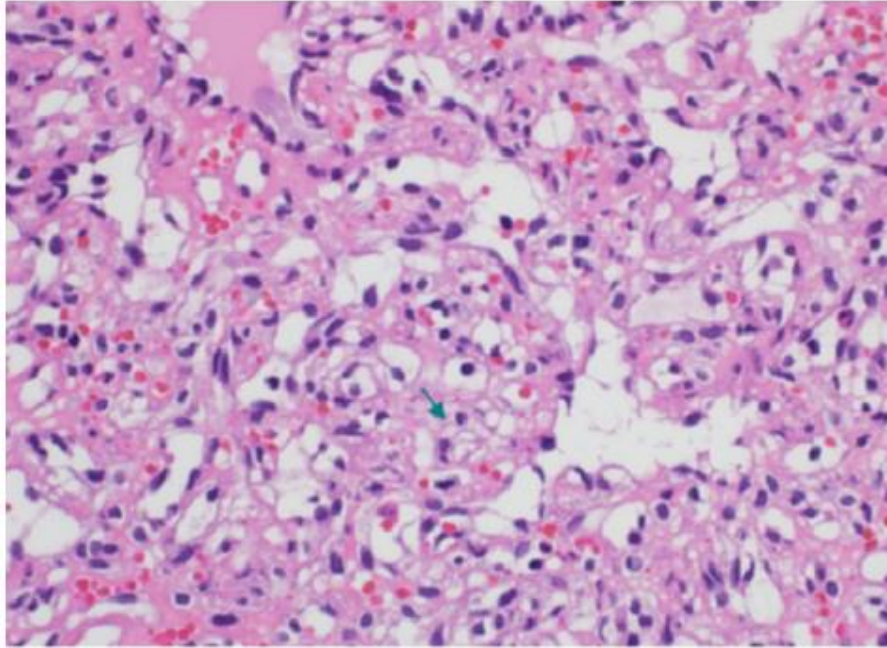


Figure 6: High power view showing interstitial tumor cells with abundant vacuolated cytoplasm (green arrow) with occasional hyperchromatic nuclei (H&E X00).

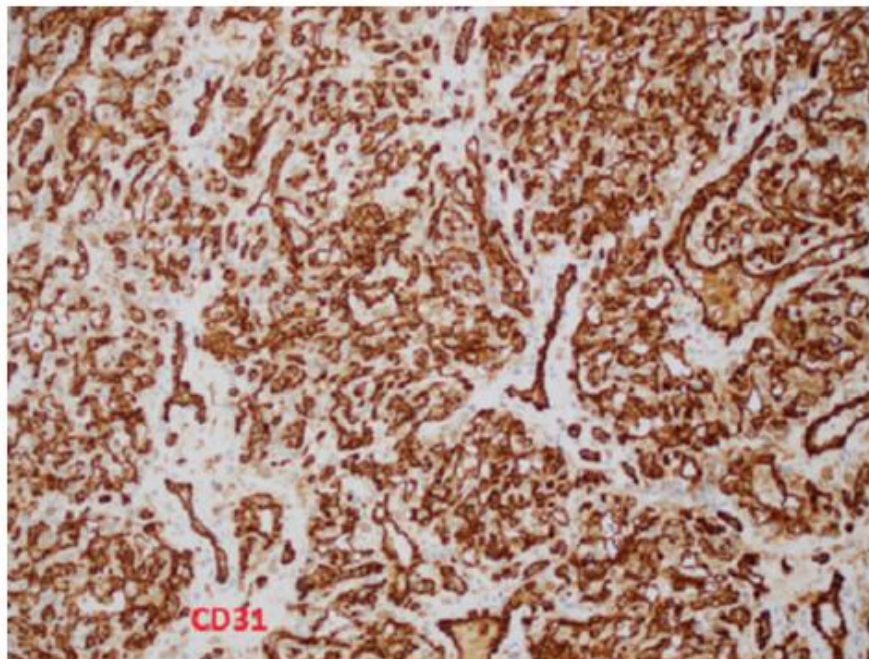


Figure 7: Immunohistochemical stain for CD31 highlights the lobulated capillaries and the rich vascular network (Immunohistochemistry X100).

1.4.1 Pathological examination: Sections show a well-circumscribed lobular proliferation of closely packed variable sized capillaries (Figure 1). The capillaries are lined by bland endothelium. The interstitium between the capillaries show stromal cell proliferation with vacuolated cytoplasm and occasional hyperchromatic nuclei (Figure 2). By immunohistochemistry, the interstitial cells are focally positive with CD68 while negative with CD31, CD34, Inhibin, EMA, GFAP and S-100. The rich capillary network is highlighted with CD34 and CD31 (Figure 3).

2. Discussion

Hemangioblastoma are benign neoplasm of the CNS and they are basically classified as meningeal lesions of uncertain origin [1, 2]. Hemangioblastomas are rare, accounting for 1-5% of all spinal cord tumours.^{K1} 75% of the Spinal hemangioblastoma are Intramedullary, and another 10-15% have combined intramedullary and extramedullary-intradural component, while isolated Extramedullary hemangioblastoma are rare^{K1} and associated with Pia mater. They most frequently are localized at the level of the cervical and thoracic vertebrae [3]. On the axial plane, the epicenters of hemangioblastomas are most commonly found in the posterior aspect of the spinal cord, in the region of the dorsal root entry zone [3, 4]. Chang Hyun Park [5], in a single center study from 2003-2012, have operated on 16 cases of Spinal Hemangioblastoma out of which 12 were solitary sporadic and 4 fulfilled the criteria of VHL, and all of these were intra-medullary. Out of the 12 solitary, 7 were cervical, 4 were thoracic and one at L1/2 level. The 4 patients with VHL had multiple and all were in cervical or thoracic region with one intramedullary at L1. This study again shows the occurrence of solitary extramedullary Lesion is a rare entity [5]. Von Hippel-Lindau syndrome is autosomal

dominant disorder with incomplete penetrance that has variable manifestations, linked to loss of function and mutation in the tumor suppressor gene on Chromosome no 3. Intramedullary Hemangioblastoma are seen in 10-30 % of patients with VHL syndrome. VHL syndrome is usually manifesting itself as central nervous system hemangioblastomas, renal cysts, and renal cell carcinomas. Other lesions include retinal angiomas, pheochromocytomas, pancreatic cysts, and epididymal cystadenomas. Tumours that are rich in blood vessels grow in the neural tissue in these tumours are called hemangioblastomas. cerebellum, cervical spine is the most common location of these tumours .spinal hemangioblastoma patients tend to present with neurological symptoms And signs at a younger age, and experience multiple small lesions .these tumours are only diagnosed when they are associated with compression effect and loss of function due to mass effect on the surrounding nervous tissue. Radical advancement of hemangioblastomas from solid to cystic component. Patients usually appear with symptoms due to mass effect, most often from an enlarging peritumoral cyst. An awareness of this advancement can assist in clinical decisions concerning follow-up intervals and the timing of surgical intervention. Our review of literature shows that a haemangioblastoma is actually rare entity and it does not occur commonly in the spinal cord. According to the literature the most common location is the posterior cranial fossa [6] and the second most common location comes out to be the spinal cord followed by spinal nerves, brain stem, thalamus and pituitary stalk [7, 8]. Infact spinal cord lesions account for very small percentage of the primary tumors overall, furthermore most of the patients that come with this lesion have actually and underline pretext to it that is VHL syndrome [9]. The actual incidence of sporadic lesion is unknown, one study [10] showed 20% of the

cases have sporadic lesions and in our case we also think that this is a sporadic and isolated lesion as the patient does not have any other manifestations of Von Hippel Lindau syndrome, clinically or radiologically. Literature shows that sporadic lesions present much later in life and have less neurological symptoms as compared to the other counterpart with VHL syndrome patients. Also these patients are at much higher risk of recurrence, These patients usually require a lifelong surveillance and serial imaging to rule out other lesions [11]. In patients with sporadic and isolated lesions of hemangioblastoma, only 4% of the patients have detectable mutations in the respective VHL gene, however, new literature shows that these mutations are only specific to hemangioblastoma and have lower penetrance [12]. Because of the slow growing nature of the tumor mostly patients are asymptomatic, gets symptomatic because of local compression of neurological tissue from the mass lesion, mostly associated with the Back Pain, which later on may involve sensory loss or motor loss. VHL syndrome is a genetic disorder that is autosomal dominant in nature, and it is caused by mutations of the VHL tumour suppressor gene which is a germline mutation present on little arm of the third chromosome (3p25-26). The prevalence is 1:40000 to 1:50000. VHL syndrome is usually manifesting itself as central nervous system hemangioblastomas, renal cysts, and renal cell carcinomas. Other lesions include retinal angiomas, pheochromocytomas, pancreatic cysts, and epididymal cystadenomas. Tumours that are rich in blood vessels grow in the neural tissue in these tumours are called hemangioblastomas. cerebellum, cervical spine is the most common location of these tumours .spinal hemangioblastoma patients tend to present with neurological symptoms And signs at a younger age, and experience multiple small lesions .these tumours are

only diagnosed when they are associated with compression effect and loss of function due to mass effect on the surrounding nervous tissue. Radical advancement of hemangioblastomas from solid to cystic component. Patients usually appear with symptoms due to mass effect, most often from an enlarging peritumoral cyst. An awareness of this advancement can assist in clinical decisions concerning follow-up intervals and the timing of surgical intervention. Tumour resection is the mainstay of management and can be curative for patients with solitary lesions, but constant follow-up is essential due to the high frequency of mutations in these patients with these tumours and a possible risk of a new tumour. Most of the literature we encountered patients had follow up for 1 to 2 years continuously. In a study done by Sven and Frank [14], and literature review follow-up after treatment for sporadic CNS hemangioblastoma were not found in the current literature. Based upon their experience they suggested to perform a MRI scan of the involved neuronal axis at 6 and at 12-24 months in the postoperative period. These follow-up modalities are to be advanced or extended based upon clinical indication. After intervention for a VHL associated lesion, there are detailed follow-up schedules available. The literature suggests performing a yearly MRI driven craniospinal control as well as an annual ophthalmoscopy, a yearly abdominal ultrasound with triennial computed tomography (CT) imaging, a yearly audiometry and pheochromocytoma investigation by urine analysis (metanephrine – VMA) Based upon clinical indication these follow-up modalities should be advanced or extended.

3. Conclusion

Tumour resection is the mainstay of management and can be curative for patients with solitary lesions, but

constant follow-up is essential due to the high frequency of mutations in these patients with these tumours and a possible risk of a new tumour. Most of the literature we encountered patients had follow up for 1 to 2 years continuously. Once considered a rare entity the actual incidence rate of isolated intradural extramedullary Hemangioblastoma still remains unknown Keeping a higher index of suspicion in mind, a thorough review of MRI can lead to higher index of diagnosis pre-operatively. Total tumor resection appears to be one of the best options of treatment.

References

1. Cushing HB, Bailey P. Tumors arising from blood vessels of the brain: angiomatous malformations and hemangioblastomas. Charles C. Thomas Springfield, IL 105 (1928): 212.
2. Rubinstein LJ. Tumors of the central nervous system. Armed Forces Institute of Pathology; sold by American Registry of Pathology (1972).
3. Lonser RR, Oldfield EH. Spinal cord hemangioblastomas. *Neurosurgery Clinics* 17 (2006): 37-44.
4. Mandigo CE, Ogden AT, Angevine PD, et al. Operative management of spinal hemangioblastoma. *Neurosurgery* 65 (2009): 1166-1177.
5. Park CH, Lee CH, Hyun SJ, et al. Surgical outcome of spinal cord hemangioblastomas. *Journal of Korean Neurosurgical Society* 52 (2012): 221.
6. Neumann HP, Eggert HR, Weigel K, et al. Hemangioblastomas of the central nervous system: a 10-year study with special reference to von Hippel-Lindau syndrome. *Journal of neurosurgery* 70 (1989): 24-30.
7. Gläsker S, Berlis A, Pagenstecher A, et al. Characterization of hemangioblastomas of spinal nerves. *Neurosurgery* 56 (2005): 503-509.
8. Kanno H, Yamamoto I, Nishikawa R, et al. Spinal cord hemangioblastomas in von Hippel-Lindau disease. *Spinal cord* 47 (2009): 447-452.
9. Kinney TD, Fitzgerald PJ. Lindauvon Hippel disease with hemangioblastoma of the spinal cord and syringomyelia. *Archives of pathology* 43 (1947): 439.
10. Takai K, Taniguchi M, Takahashi H, et al. Comparative analysis of spinal hemangioblastomas in sporadic disease and Von Hippel-Lindau syndrome. *Neurologia medico-chirurgica* 50 (2010): 560-567.
11. Conway JE, Chou D, Clatterbuck RE, et al. Hemangioblastomas of the central nervous system in von Hippel-Lindau syndrome and sporadic disease. *Neurosurgery* 48 (2001): 55-63.
12. Woodward ER, Wall K, Forsyth J, et al. VHL mutation analysis in patients with isolated central nervous system haemangioblastoma. *Brain* 130 (2007): 836-842.
13. Murota T, Symon L. Surgical management of hemangioblastoma of the spinal cord: a report of 18 cases. *Neurosurgery* 25 (1989): 699-708.
14. Bamps S, Van Calenbergh F, De Vleeschouwer S, et al. What the neurosurgeon should know about hemangioblastoma, both sporadic and in Von Hippel-Lindau disease: A literature review. *Surgical neurology international* 4 (2013).



This article is an open access article distributed under the terms and conditions of the [Creative Commons Attribution \(CC-BY\) license 4.0](https://creativecommons.org/licenses/by/4.0/)