

## Research Article

# Laser Ablation of Metastatic Lymph Nodes in the Neck for Oral Carcinoma-Technique and Viability of the Procedure

Rusy Bhalla<sup>1\*</sup>, Seemantini Bhalla<sup>1</sup>, Duleep Bhonsale<sup>2</sup>, Ashish Kapadia<sup>2</sup>

<sup>1</sup>Department of Oncology, Orchid Center for Laser surgery, Mumbai, India

<sup>2</sup>Department of Radiology, Orchid Center for Laser surgery, Mumbai, India

\***Corresponding Author:** Dr. Rusy Bhalla, S1 Link Square mall, Opp KFC Linking Road, Bandra west, Mumbai 400050, India, E-mail: [rusybhalla@gmail.com](mailto:rusybhalla@gmail.com)

**Received:** 12 March 2021; **Accepted:** 22 March 2021; **Published:** 26 March 2021

**Citation:** Rusy Bhalla, Seemantini Bhalla, Duleep Bhonsale, Ashish Kapadia. Laser Ablation of Metastatic Lymph Nodes in the Neck for Oral Carcinoma-Technique and Viability of the Procedure. Journal of Radiology and Clinical Imaging 4 (2021): 027-035.

### Abstract

**Background:** Presence of macro and microdisease in the neck in cases of Oral carcinoma is a major barrier in full recovery of the patient. Conventionally the problem has been handled by Neck dissection popularly referred to as Radical Neck dissection and its many variants like Modified neck dissection and supraomohyoid dissection. The surgery assumes that removal of the fat containing lymph nodes is effective in spread of the disease. The major stumbling block is presence of extra nodal spread in

enlarged lymph nodes. Percutaneous lymph node laser ablation (PLALN) is becoming more popular in many centers for necrosing the lymph nodes effectively without the neck dissection. There are obvious advantages and disadvantages to this procedure. This study was aimed at verifying the effectiveness of the procedure and aimed to understand the reason for success and failure if any. Attempt has also been made to understand the Anatomy of Neck Lymphatic system and understand the cellular

structure of lymph nodes which would make the procedure effective.

**Patients and Methods:** 46 patients were of oral carcinoma were included in this observational study. These patients were having Metastatic lymph nodes on Ultrasonography and MRI scans prior to the procedure. The primary tumours were handled by Laser ablation and PLALN was carried out as a part of the procedure.

**Results:** The procedure was safe and effective in 100 % of cases in necrosing the lymph nodes less than 2.0 cms in longest diameter. It was 70% effective in handling lymph nodes more than 2.0 cms in diameter. It was less than 20% effective in handling lymph nodes more than 3.5 cms in diameter. There was no major side effect of the procedure in any patient.

**Conclusion:** PLALN is an effective procedure for handling of Metastatic lymph nodes in early stages.

**Keywords:** Lymph node management; Laser ablation; Oral cancer

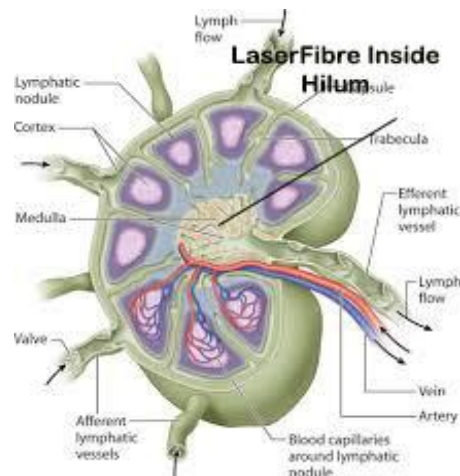
## 1. Introduction

Thermal ablation is gaining popularity in destruction of tumours in various centers of the world. (Emiliano). Laser ablation is now a recognized procedure approved by USFDA for soft tissue tumours [1].

Main methods of laser Ablation include [2].

1. Radiofrequency
2. Microwave
3. Cryoablation
4. Laser.

Laser offers a controlled thermal ablation with real time visualization under sonography control. In all recent studies therefore laser is becoming increasingly popular in multiple clinical conditions for soft tissue tumours namely Liver, Lung, Thyroid, Oral malignancies [3-7]. Laser ablation for Unresectable Mesentric lymph nodes has been performed with promising results [8]. Lymph nodes are present in a majority of oral cancer patients. Enlarged lymph nodes present as swelling in the submandibular region (Figure 4). In late stages of Carcinoma of oral cavity lymph nodes more than 2.5 cms were present. Most of these lymph nodes had a breach of capsule (Figure 10). Conventionally Lymph nodes in operable cases are handled by neck dissection. The extent of dissection may vary depending on the severity of the case [9]. PLALN was a part of procedure of ablation of Primary Carcinoma through laser ablation [6]. To understand the efficacy of PLALN one must take a look at the anatomy of a lymph node and the lymphatic system. The neck lymphatic system is divided into lymphatics and lymph nodes draining into subclavian vein. Metastatic cells traverse the lymphatics to reach the lymph nodes. Important observation is that they do not multiply in the lymphatics since there is no blood supply inside, but serve only for transit passage for the lymph nodes. The lymph node has an afferent artery and lymphatic vessels and efferent veinule and lymphatic vessel. It is covered by the capsule (Figure 1).



**Figure 1:** Anatomy of Lymph Node with laser fiber in Hilum.

Any increase in volume due to metastasis is reflected in the following way (Figure 8).

1. Loss of fatty hilum.
2. Increase in size
3. Loss of oval structure to a round shape.
4. Further increase can outstrip the blood supply and cause necrosis of the central area.

Destruction of fatty hilum by laserising it effectively devascularises the lymph node and leads to necrosis of the lymph node. (Figure 9). This causes a direct and indirect necrosis of the metastatic cells. Over a period the necrosed lymph node is reabsorbed (Figures 5, 6 and 7). The Radical neck dissection (RND) in late stages of Oral carcinoma has a high recurrence rate especially in enlarged lymph nodes [10]. The recurrence rates in stage 4 lesions are ranging from 30 to 70% [11, 12]. There is however no significant survival noted in the extent of RND [11]. On examining through the literature we could not find any reference as to

the reason for recurrence after RND and nature of recurrence.

Our group postulated the reason for metastatic deposits as thus below

Removal of the lymphatic system by neck dissection leads to opening of afferent lymphatics and in presence of metastatic cells in the lymphatic vessels leads to a spillage in the neck spaces and leads to an implantation of metastatic cells. A good blood supply due to dissection in the operated areas leads to a growth of metastatic cells in the opened neck spaces. Recurrence rates are seen to be higher in clinically palpable lymph nodes. Various studies give figures from 20 to 30% [13]. Neck dissection in clinically enlarged lymph nodes may become the direct cause of metastatic deposits in the neck. These are mistakenly referred as lymph nodes. The difference can be made out by lack of capsule in these deposits on sonography.

## 2. Patients and Methods

46 patients were included in the study (Figure 2) The procedure was explained in detail to the patients. The procedure was carried out under General anaesthesia. All patients had a primary oral carcinoma which was handled by Laser Ablation. The PLALN was a part of the procedure. The lymph nodes were visualized under sonography control and an 18 No needle was manipulated percutaneously to the center of the lymph node (Figures 3, 8). The fiber was activated and the center of lymph node was laserised including the surrounding upto the capsule. Larger lymph

nodes had laserisation upto and including the capsular area. The result was a hyperechogenic lymph node (Figure 11).

## 3. Results

All patients tolerated the procedure well. There was no intraoperative complications. 8 patients had a hematoma which was managed by compression. Most lymph nodes showed a full regression in 2 months (Figures 4-7). Results have shown that efficacy of the procedure is inversely proportional to the size of the lesion due to extracapsular spread in larger lymph nodes (Figure 3).

### Demography of patients

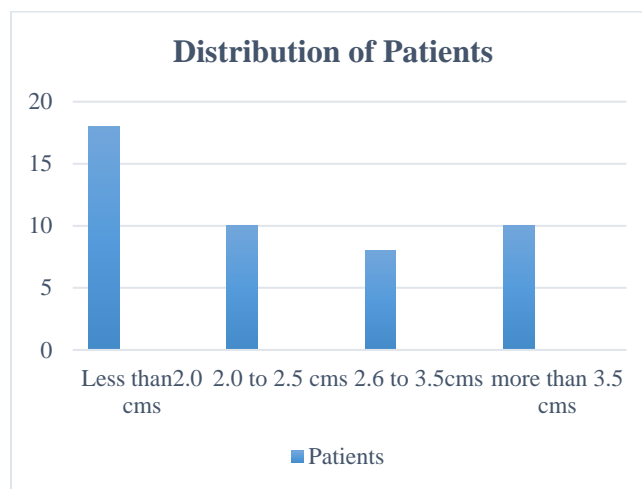
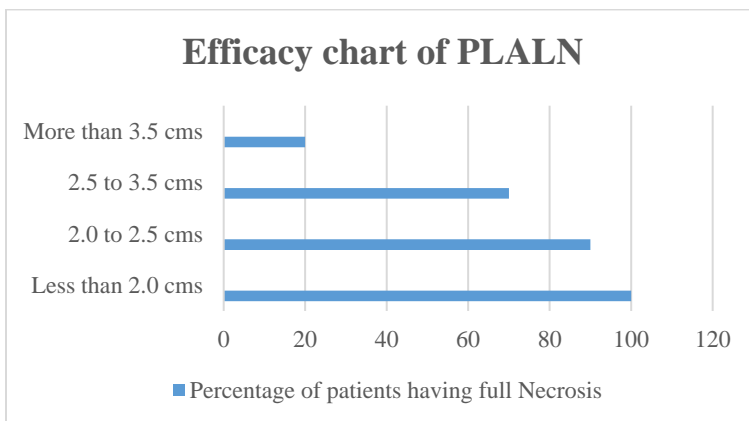
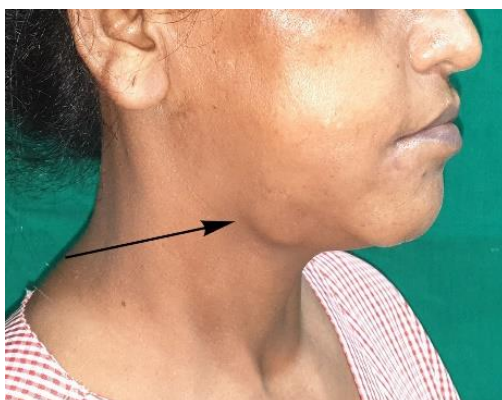

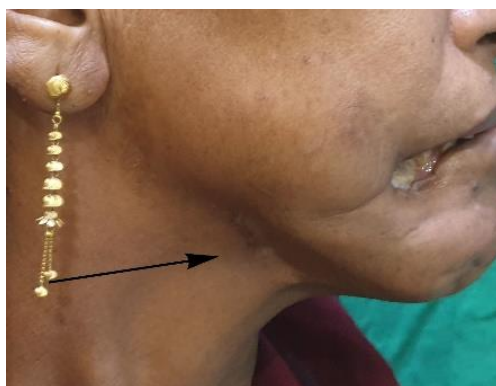Figure 2: The distribution of patients with size of lymph nodes.



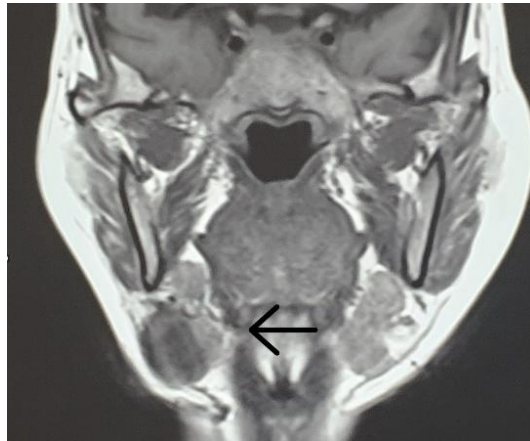
**Figure 3:** Percentage of patients having 100% necrosis grouped by size of Lymph Nodes Visualized on sonography after 4 weeks.



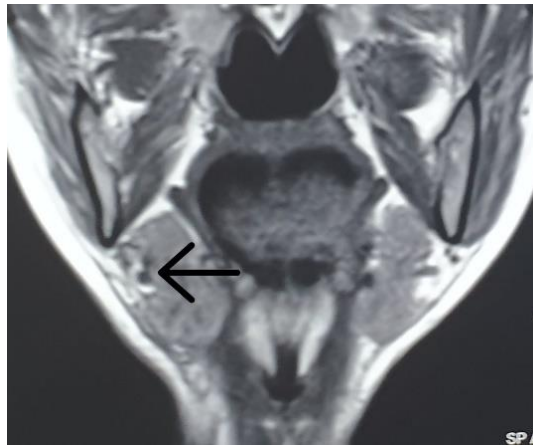
**Figure 4:** Lymph Node swelling with Arrow pointing to the swelling.



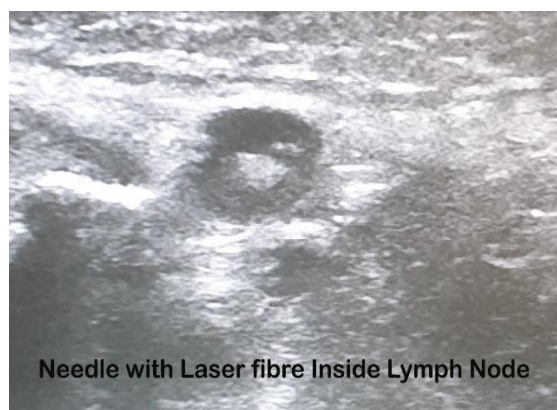
**Figure 5:** Arrow pointing to resolution of Lymph Node. Oral deformity due to Laser ablation at angle of mouth involvement.



**Figure 6:** Arrow pointing to Submandibular Lymph Node.

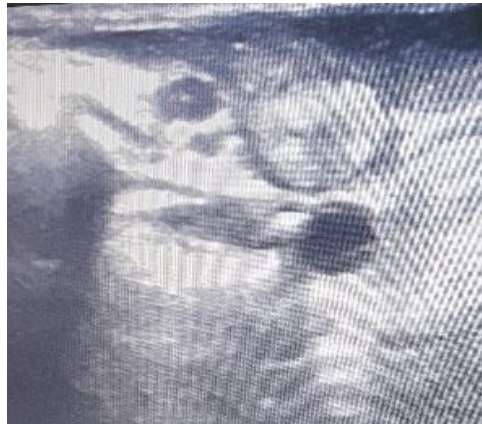

**Figure 7:** Arrow pointing to Total resolution of Swelling.

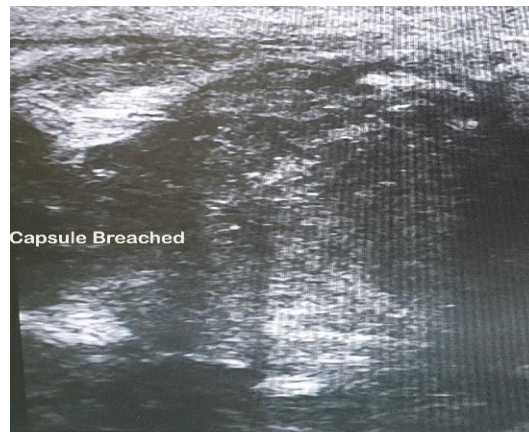


**Figure 8:** Needle with Laser fibre inside Lymph Node. Note round shape and lack of fatty hilum.

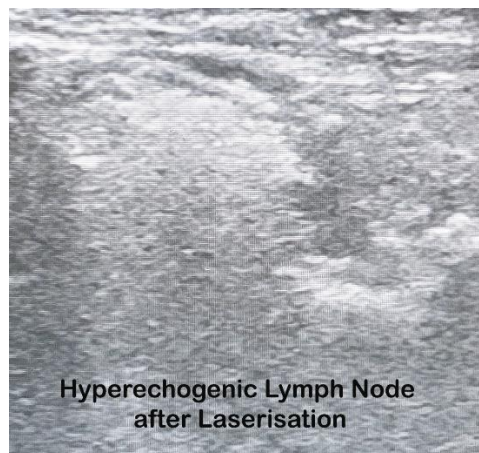




**Figure 9:** Post PLALN picture of Necrosed Lymph Node showing Hyperechogenicity ,seen after 2 weeks. The lymph Node is lying above Jugular vein.



**Figure 10:** Large lymph node in neck showing breach of capsule.



**Figure 11:** Hyperechogenic Lymph Node immediately after laserisation.

#### **4. Discussion**

With rapid development of imaging technology, Surgery is becoming more focused and minimal. Laser ablation is playing a very important part in this regard [1, 6, 14]. The most common methods used are Radiofrequency and laser for ablation techniques [7]. Laser ablation of lymph nodes is being practiced in select centers due to different skill sets requirements from conventional surgery. The laser destruction of tissue including tissue protein denaturation, coagulative necrosis, tissue liquefaction, vaporization, and carbonization occurs instantaneously [15]. Lymph node management especially in inaccessible or areas close to major vessels has always been difficult to treat with conventional surgery. Many studies have used Laser for Lymph nodes in neck for thyroid carcinoma and Mesentric lymph Nodes. The easy application of sonography and appropriate laser makes it a worthwhile alternative for inoperable patients. The results have been encouraging from all quarters. Presence of Lymph Node places the patient in stage 3. Enlarged lymphnode or multiple lymph nodes places the patient in stage 4 [16]. The ability to laserise the enlarged lymph nodes adds to the survival period of patients [4, 6, 7, 14, 17].

#### **5. Conclusion**

PLALN is a safe and viable procedure for accessible and inaccessible lymph nodes in Oral carcinoma. The procedure is predictable for smaller lymph nodes. The procedure has its advantages since the destruction can be done in real time. Earlier presentation is necessary for taking full advantage of the procedure in oral carcinoma. PLALN is a skilled procedure and requires a training in Interventional sonography.

#### **Funding and Conflict of Interests**

The authors declare that they have no funding and there is no conflicting interests.

#### **References**

1. Radiation-Emitting Products, Surgical and Therapeutic Products, Medical Lasers. FDA (2020).
2. Emiliano Schena, Paola Saccomandi and Yuman Fong. Laser Ablation for Cancer: Past, Present and Future. *J Funct Biomater* 8 (2017): 19.
3. Pacella CM, Mauri G, Achille G, et al. Outcomes and Risk Factors for Complications of Laser Ablation for Thyroid Nodules: A Multicenter Study on 1531 Patients. *The Journal of clinical endocrinology and metabolism* 100 (2015): 3903-3910.
4. Wu X, Zhou P, Ma S, et al. Ultrasound-guided laser thermal ablation for treatment of small liver cancer at high-risk sites. *Nan fang yi ke da xue xue bao = Journal of Southern Medical University* 36 (2016): 120-125.
5. Mauri G, Cova L, Monaco CG, et al. Benign thyroid nodules treatment using Percutaneous Laser Ablation (PLA) and Radiofrequency Ablation (RFA). *International journal of hyperthermia* 33 (2017): 295-299.
6. Rusy Bhalla, Seemantini Bhalla, Duleep Bhonsale, et al. Laser Ablation Surgery in Late Stage Buccal Cancer. *Cancer and Oncology Research* 6 (2020): 47-52.
7. Machi J, Oishi AJ, Furumoto NL, et al. Sonographically guided radio frequency thermal ablation for unresectable recurrent tumors in the retroperitoneum and the pelvis. *J Ultrasound Med* 22 (2003): 507-513.



8. Jiang T, Deng Z, Tian G, et al. Percutaneous laser ablation: a new contribution to unresectable high-risk metastatic retroperitoneal lesions?. *Oncotarget* 8 (2017): 2413-2422.
9. Jatin P Shah, Ziv Gil. Current Concepts In Management Of Oral Cancer-Surgery. *Oral Oncol* 45 (2009): 394-401.
10. Lim JY, Lim YC, Kim SH, et al. Factors predictive of successful outcome following salvage treatment of isolated neck recurrences. *Otolaryngol Head Neck Surg* 142 (2010): 832-837.
11. Andersen PS, Chakera AH, Thamsborg AK, et al. Recurrence and survival after neck dissections in cutaneous head and neck melanoma. *Dan Med J* 61 (2014): A4953.
12. Jones AS, Tandon S, Helliwell TR, et al. Survival of patients with neck recurrence following radical neck dissection: utility of a second neck dissection? *Head Neck* 30 (2008): 1514-1522.
13. Wang B, Zhang S, Yue K, et al. The recurrence and survival of oral squamous cell carcinoma: a report of 275 cases. *Chin J Cancer* 32 (2013): 614-618.
14. Mauri G, Cova L, Tondolo T, et al. Percutaneous laser ablation of metastatic lymph nodes in the neck from papillary thyroid carcinoma: preliminary results. *J Clin Endocrinol Metab* 98 (2013): 1203-1207.
15. Ehsan Azma and Nassimeh Safavi. Diode Laser Application in Soft Tissue Oral Surgery Ehsan Azma and Nassimeh Safavi. *J Lasers Med Sci* 4 (2013): 206-211.
16. Neukam FW, Stelzle F. Laser tumor treatment in oral and maxillofacial surgery. *Physics Procedia* 5 (2010): 91-100.
17. Oral Cavity and Oropharyngeal Cancer Stages. Early Detection, Diagnosis, And Staging. *Cancer* (2021).
18. Pacella CM, Francica G, Di Lascio FM, et al. Long-term outcome of cirrhotic patients with early hepatocellular carcinoma treated with ultrasound-guided percutaneous laser ablation: a retrospective analysis. *Journal of clinical oncology* 27 (2009): 2615-2621.



This article is an open access article distributed under the terms and conditions of the [Creative Commons Attribution \(CC-BY\) license 4.0](https://creativecommons.org/licenses/by/4.0/)