

## Research Article

---

# Investigating the Impact of the Amount of Contrast Material used in Abdominal CT Examinations Regarding the Diagnosis of Appendicolith

Eleftherios Lavdas<sup>1,2</sup>, Nadia Boci<sup>2</sup>, Lia Sarantaenna<sup>2</sup>, Maria Papaioannou<sup>2</sup>, Ioannis Ntavelis<sup>3</sup>, Theodoros Theodoropoulos<sup>4</sup>, Lida Gogou<sup>1</sup>, Panayiotis Mavroidis<sup>5\*</sup>

<sup>1</sup>Department of Medical Radiological Technologists, Technological Education Institute of Athens, Greece

<sup>2</sup>Department of Medical Imaging, Animus kyanoy Larisas Hospital, Larissa, Greece

<sup>3</sup>Department of Gastroenterology, Animus kyanoy Larisas Hospital, Larissa, Greece

<sup>4</sup>Department of Surgery, Animus kyanoy Larisas Hospital, Larissa, Greece

<sup>5</sup>Department of Radiation Oncology, University of North Carolina, Chapel Hill, NC, USA

**\*Corresponding Author:** Panayiotis Mavroidis, Associate Professor, Department of Radiation Oncology, University of North Carolina, 101 Manning Drive Chapel Hill, NC 27599-7512, USA, Tel: +1 984 974-8438, Fax: +1 919 843-9127, E-mail: [panayiotis\\_mavroidis@med.unc.edu](mailto:panayiotis_mavroidis@med.unc.edu)

**Received:** 04 December 2018; **Accepted:** 24 December 2018; **Published:** 28 December 2018

## Abstract

**Purpose:** Acute appendicitis is a clinical emergency and is one of the more common causes of acute abdominal pain. Consequently, to avoid significant unpleasant consequences it is necessary have early diagnosis and treatment. Commonly, in patients with signs of appendicitis an abdominal computed tomography (CT) examination should be performed.

**Materials/methods:** Out of 12 cases of patients with acute appendicitis. The presence of an appendicolith was one common finding in the CTs of those cases. Almost one third of patients show the presence of appendicoliths, which may have prognostic importance since their presence has been associated with increased likelihood for appendiceal perforation.

**Results:** In the first case, a young adult underwent a CT examination with incomplete oral administration of contrast material. This revealed the existence of an appendicolith, which caused acute appendicitis. The second patient with acute appendicitis is an adult who was diagnosed 40 days after his CT pyelography, in which small appendicoliths were not observed.

**Conclusion:** In cases where there is suspicion for acute appendicitis, nephrolithiasis and ureterolithiasis, it is proposed to CT scan the patient without oral contrast material. This targeted pelvis CT scan should be of low dose covering the region of cecum. Subsequently, oral and IV contrast should be administered and an enhanced CT should be acquired to succeed gastric intestinal differentiation. In this way, we can avoid covering the lower abdomen and identify better any small stones.

**Keywords:** Acute appendicitis; Appendicoliths; Nephrolithiasis; Computed Tomography (CT); Contrast material

## 1. Introduction

A very common life-threatening condition, which requires early diagnosis is acute abdomen. Often, emergency surgery is necessary. Acute appendicitis is the most common source for this symptom and the lifetime probability for acute appendicitis is approximately 7% (8.6% for males and 6.7% for females) [1-4]. Although a surgical procedure can efficiently treat appendicitis, the rate/risk of appendectomy is much lower for males than for females (12% vs. 23%) [3-4]. The data from the medical record of the patient is commonly used for the clinical diagnosis (e.g. positive signs of appendicitis, psoas sign in the physical examination, fever and elevated inflammation values in lab tests). If a definitive diagnosis of appendicitis has not been reached after the results of the physical examination, anamnesis, lab tests and transabdominal ultrasound (U/S) (and having excluded the possibility of pregnancy), a Computed Tomography (CT) examination of the abdomen should be performed. This should be especially the case for patients with atypical signs of appendicitis or suspected perforation [5]. Based on the above description, it appears that radiological imaging can be critical for diagnosis of appendicitis. In the case of suspected appendicitis, the level of the effective CT dose used in both the unenhanced and contrast-enhanced CT scans is significant.

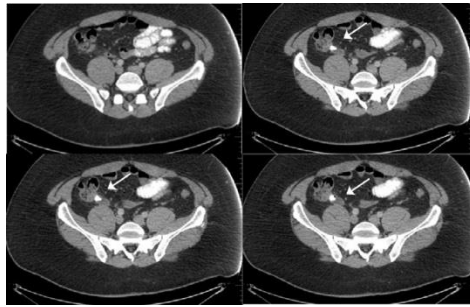
The present study involved 12 patients, who underwent CT examination in suspicion of appendicitis. A common finding in the CTs of those patients was the presence of an, which may have prognostic importance. It has been reported that the likelihood of appendiceal perforation increases in the presence of appendicoliths. This report performs an analytical reviews and presents the data of two representative patients of this cohort aiming at proposing a course of action that could resolve this issue clinically.

## 2. Methods

### 2.1 Case 1

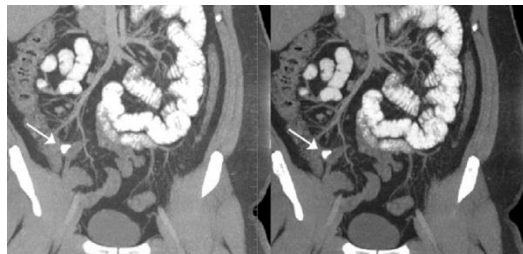
A male (34 y) underwent a CT examination for an acute abdominal pain in the upper abdomen. The abdominal examination showed a soft abdomen with tenderness localized to the right lower quadrant. A very comprehensive medical examination was performed on this patient, which included blood tests, U/S of the upper abdomen and kidneys and x-ray of the abdomen. Finally, a CT scan of the entire abdomen and pelvis was acquired after the administration (both oral and IV) of contrast material. The blood examination revealed white blood cells (WBC) of 18.4 (103/mm<sup>3</sup>), hemoglobin of 15.3 g/L, urea 27 mmol/L and creatinine 0.98 µmol/L. Both kidneys gallbladder and

spleen showed normal appearance in the U/S. Additionally, no pathological findings were observed in the x-ray images. Oral contrast material less than 500 ml was received by the patient because of his non-cooperative condition due to his abdominal pain.



**Figure 1:** CT axial images of the lower abdomen, which show the appendicolith (arrows). This subject was in a non-cooperative condition. Small intestine is enhanced instead of colon which is not enhanced. There is an inflamed appendix because of the presence of the appendicolith.

A severely inflamed appendix was revealed by the CT of the abdomen (dilated at 1.1 cm). A 1.4 cm appendicolith was also identified as shown in Figures 1 and 2. One significant observation was that the appendicolith that existed in the lower abdomen could be revealed due to the fact that the oral contrast material covered the upper only part of the abdomen. If the patient had received the complete amount of contrast material (1000 ml), the appendicolith that caused the inflammation would have been hidden because the whole abdomen would have been covered with contrast.

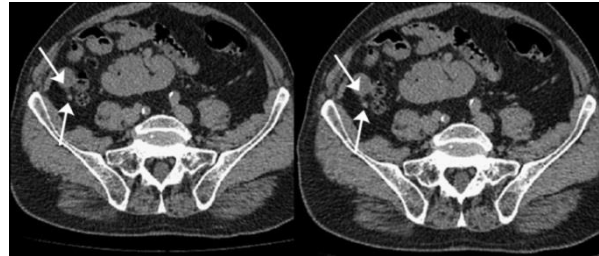


**Figure 2:** CT coronal reconstructed images of the abdomen showing the right sided appendicitis with the appendicolith (arrows). This subject was in a non-cooperative condition. Small intestine is enhanced instead of colon which is not enhanced.

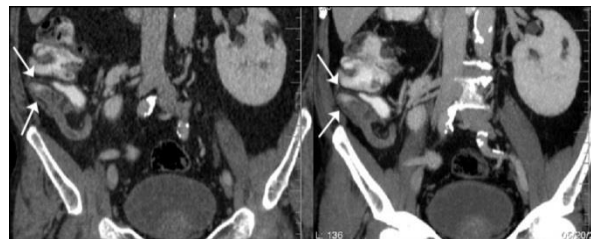
## 2.2 Case 2

A male (66 y) came with a high fever and an acute abdominal pain in the upper abdomen. For this patient a very comprehensive medical examination was performed too, which included blood tests, U/S of the upper abdomen and kidneys and x-ray of the abdomen. Finally, a CT scan of the entire abdomen and pelvis was also acquired with and without the administration of oral of contrast material. The blood tests revealed that the values of WBC were high. Both kidneys gallbladder and spleen showed normal appearance in the U/S. Additionally, no pathological findings

were observed in the x-ray images. A severely inflamed appendix (dilated at 9.0 x 2.5) was revealed by the CT scan as shown in Figures 3 and 4. Those finding were examined against the finding from a CT pyelography, which had been acquired 40 days ago. This scan showed that there were small appendicoliths in the appendix, which were not controlled.



**Figure 3:** CT axial images of the lower abdomen, which show the appendicolith (arrows). The scan was acquired without administration of contrast material.



**Figure 4:** Coronal images of the abdomen. The appendicolith does not have a good definition because of the presence of the contrast material in the appendix (arrows).

### 3. Discussion

Recent reports have estimated that the appendectomy rate may be close to 15%. However, one way to reduce it has been the performance of proper imaging examinations [6]. The most common imaging modalities that are applied are U/S, abdominal CT and magnetic resonance imaging (MRI). Van Randen et al. [7] analyzed the data of 671 patients with verified acute appendicitis, who were examined with both U/S and CT. The sensitivity and specificity values for U/S they were 78% and 83%, whereas for CT they were 91% and 90%, respectively. More specifically, CT appears to be 93 to 98 percent accurate in confirming or ruling out appendicitis [8-12]. Coursey et al. [13] evaluated the correlation between the acquisition of abdominal CT and its effect on the negative appendectomy rate in patients with suspected appendicitis. According to their findings, there was an increase in CT scans by 74.7% (from 18.5% to 93.2%) over a period of 10 years, which resulted in a reduction in the rate of appendectomies by 8% (from 16.7% to 8.7%) [13].

Regarding the clinical evaluation of the acquired CT images, special attentions should be paid by the radiologist to the following 5 signs of appendicitis: 1) Presence of an enlarged appendix with a diameter exceeding 6 mm (in the absence of perforation this is the most important parameter); 2) Appendiceal wall with thickness exceeding 2 mm; 3) Inflammatory compression of the adjoining adipose tissue; 4) Calcified appendicolith; 5) Abscess formation in the right lower abdomen [14-16]. In the first case that is presented here, the appendicolith that caused this patient's inflammation was revealed in the lower abdomen because a reduced amount of contrast material had been administered to him, which had covered only the upper part of his abdomen (Figures 1 and 2). If the patient had received the full amount of contrast material, the appendicolith would have been hidden since the whole abdomen would have been covered with that contrast material.

In the second case, 40 days before the onset of the symptoms, a CT pyelography of the patient had been acquired, which showed that there was a calcified appendicolith within the thickened appendix. The presence of the appendicolith was not observed or not given the prognostic importance of the appearance of appendicitis. Ishiyama et al. [17] retrospectively studied 254 patients, who had verified acute appendicitis, and they showed that there is a significant relationship between the severity of acute appendicitis and the presence of appendicolith. In this analysis, it was shown that not only the presence of appendicoliths was important but also its location (the root of the appendix was significantly associated with gangrenous appendicitis) [17].

In all of the studied cases, we started the CT protocol with a targeted pelvis CT scan of low dose in the region of cecum without the administration of contrast material and then proceeded with the regular CT using contrast. The purpose of the unenhanced CT is to help us reveal an appendicolith. The contrast-enhanced CT gives a good bowel opacification that is essential for a CT abdomen scan. The use of bolus IV contrast and dynamic scanning are necessary not only for the optimization of the examination but it also shows if the appendix has a wall thickening or ring-shaped contrast enhancement, which is important for the diagnosis. Furthermore, the administration of IV contrast helps in the characterization of some complications such as appendiceal perforation, abscess formation, extra-appendiceal fluid collections, and septic seeding of the mesenteric-portal venous system. The diagnosis of acute appendicitis on the CT scan should indicate either an abnormal appendix or an appendicolith, due to the fact that all inflammatory processes located in the region of the appendix can cause inflammatory stranding of the mesenteric fat.

#### **4. Conclusion**

In the clinical cases that there is suspicion of acute appendicitis, nephrolithiasis and ureterolithiasis, the present study recommends the acquisition of an abdominal CT applying however the following workflow. The CT protocol should apply first a low-dose pelvis CT scan in the region of cecum without contrast material. Subsequently, a second CT scan should be acquired with the use of oral and IV contrast. Furthermore, we propose the performance of an additional examination to identify the presence of appendicoliths as this may be of prognostic importance for appendiceal perforation.

### Funding Information

This research did not receive any specific grant from funding agencies in the public, commercial, or not-for-profit sectors.

### Conflicts of Interest

The authors declare that they have no conflict of interest.

### References

1. Petroianu A. Diagnosis of acute appendicitis. *Int J Surg* 10 (2012): 115-119.
2. Hardin DM Jr. Acute Appendicitis: Review and update. *Am Fam Physician* 60 (1999): 2027-2034.
3. Keyzer C, Tack D, De Maertelaer V, et al. Acute appendicitis: comparison of low-dose and standard-dose unenhanced multi-detector row CT. *Radiology* 232 (2004): 164-172.
4. Addiss DG, Shaffer N, Fowler BS, et al. The epidemiology of appendicitis and appendectomy in the United States. *Am J Epidemiol* 132 (1990): 910-925.
5. Karul M, Berliner C, Keller S, et al. Imaging of appendicitis in adults. *Rofo* 186 (2014): 551-558.
6. Gorter RR, Eker HH, Gorter-Stam MA, et al. Diagnosis and management of acute appendicitis. EAES consensus development conference 2015. *Surg Endosc* 30 (2016): 4668-4690.
7. Van Randen A, Bipat S, Zwinderman AH, et al. Acute appendicitis: Metaanalysis of diagnostic performance of CT and graded compression US related to prevalence of disease. *Radiology* 249 (2008): 97-106.
8. Balthazar EJ, Megibow AJ, Siegel SE, et al. Appendicitis: prospective evaluation with high-resolution CT. *Radiology* 180 (1991): 21-24.
9. Malone AJ Jr, Wolf CR, Malmed AS, et al. Diagnosis of acute appendicitis: Value of unenhanced CT. *AJR Am J Roentgenol* 160 (1993): 763-766.
10. Balthazar EJ, Birnbaum BA, Yee J, et al. Acute appendicitis: CT and US correlation in 100 patients. *Radiology* 190 (1994): 31-35.
11. Rao PM, Rhea JT, Novelline RA, et al. Helical CT technique for diagnosis of appendicitis: Prospective evaluation of a focused appendix CT examination. *Radiology* 202 (1997): 139-144.
12. Rao PM, Rhea JT, Novelline RA, et al. Helical CT combined with contrast material administered only through the colon for imaging of suspected appendicitis. *AJR Am J Roentgenol* 169 (1997): 1275-1280.
13. Coursey CA, Nelson RC, Patel MB, et al. Making the diagnosis of acute appendicitis: Do more preoperative CT scans mean fewer negative appendectomies? A 10-year study. *Radiology* 254 (2010): 460-468.
14. Karul M, Avanesov M, Yamamura J. Acute appendicitis: A clinical diagnosis?. *Radiology* 52 (2012): 1089-1890.
15. Kim K, Kim YH, Kim SY, et al. Low-dose abdominal CT for evaluating suspected appendicitis. *N Engl J Med* 366 (2012): 1596-1605.

16. Lai V, Chan WC, Lau HY, et al. Diagnostic power of various computed tomography signs in diagnosing acute appendicitis. Clin Imaging 36 (2012): 29-34.
17. Ishiyama M, Yanase F, Taketa T, et al. Significance of size and location of appendicoliths as exacerbating factor of acute appendicitis. Emergency Radiology 20 (2013): 125-130.

**Citation:** Eleftherios Lavdas, Nadia Boci, Lia Sarantaenna, Maria Papaioannou, Ioannis Ntavelis, Theodoros Theodoropoulos, Lida Gogou, Panayiotis Mavroidis. Investigating the Impact of the Amount of Contrast Material used in Abdominal CT Examinations Regarding the Diagnosis of Appendicolith. Journal of Radiology and Clinical Imaging 1 (2018): 017-023.



This article is an open access article distributed under the terms and conditions of the [Creative Commons Attribution \(CC-BY\) license 4.0](https://creativecommons.org/licenses/by/4.0/)