


**Case Report**

## Impact of Non-surgical Spinal Decompression Combined Protocol on a Lumbar Disc Herniation Predisposing the Patient to Surgical Intervention - A Case Study

**Cristiano Vicari\***

### Abstract

**Background:** Although conservative treatment is the first choice for patients with lumbar disc herniation symptoms, in the case of sciatica, progressive neurological deficits and confirmation of extensive herniation from MRI, surgical intervention is indicated. Despite the existence of factors predisposing the patient to surgery, around 3% to 43% of patients experience recurrence of their symptoms following lumbar decompressive surgery.

**Case Report:** A 49-year-old female recreational kite surfer doing a sedentary job as a secretary complained of acute sciatic pain after intensive gardening. The initial physical therapy examination revealed a suspicion of a herniated disc in the L5 area, which was confirmed by an MRI. Despite the length of the herniation exceeding 1 cm associated with significant sciatic symptoms predisposing the patient to surgery, a non-invasive approach combining non-surgical spinal decompression with high-intensity repetitive peripheral magnetic stimulation (RPMS) was chosen. The final examination revealed a significant improvement in symptoms and MRI findings after ten combined sessions.

**Conclusion:** The combination of non-surgical spinal decompression and RPMS therapy represents a promise for patients who are indicated for surgical intervention, but prefer an alternative non-invasive treatment without the risk of side effects and the need for post-operative recovery.

**Keywords:** Lumbar disc herniation; Non-invasive approach; Non-surgical spinal decompression; Repetitive peripheral magnetic stimulation; Extensive herniation; Case study; Non-surgical approach; Combined treatment program

### Abbreviations

The following abbreviations are used in this manuscript:

**MRI:** Magnetic resonance imaging; **RPMS:** Repetitive peripheral magnetic stimulation; **BMI:** Body mass index

**VAS:** Visual analog scale; **MRC:** Medical Research Council

### Introduction

Lumbar spine is a frequent source of pain and limitation in daily activities and work, as low back pain is the most frequent worldwide musculoskeletal problem affecting approximately 80% of the population at least once in a lifetime [1,2]. This lower part of the spine creates a lordotic curvature via five vertebrae and five intervertebral discs. It is the intervertebral discs, made

### Affiliation:

<sup>1</sup>BScPT at rehabilitation center Futurafisio, Latina, Italy

### \*Corresponding author:

Cristiano Vicari, BScPT at rehabilitation center Futurafisio, Latina, Italy.

**Citation:** Cristiano Vicari. Impact of Non-surgical Spinal Decompression Combined Protocol on a Lumbar Disc Herniation Predisposing the Patient to Surgical Intervention - A Case Study. Journal of Spine Research and Surgery. 6 (2024): 31-35

**Received:** April 17, 2024

**Accepted:** April 23, 2024

**Published:** April 26, 2024

up of three basic building blocks - nucleus pulposus, annulus fibrosus, and the cartilaginous endplates, that are a frequent source of pain and limitation [2]. As a result of aging and subsequent degeneration, loss of hydration and weakening of the nucleus pulposus or as a result of trauma due to excessive load on the spinal segment, the nucleus pulposus herniates through the annulus fibrosus [3]. This condition, generally called disc herniation, is often accompanied by burning and stinging pain that can radiate to the lower limbs [4]. Larger herniations can cause spinal nerve compression, the primary cause of sciatica. Increased pressure and nerve root irritation is manifested by unilateral leg pain radiating beyond the knee and into the toes and foot, decreased muscle strength, sensory deficits and movement limitation [5,6].

Conservative treatment of sciatica focuses primarily on suppressing pain, either by administering analgesics or reducing pressure on the nerve root. If magnetic resonance imaging (MRI) confirms disc herniation in a patient with sciatic symptoms, or this finding is accompanied by progressive neurological deficits, surgical intervention is indicated [6]. Despite the fact that the pain and symptoms of sciatica and their correlation with MRI findings are often the main factors predisposing the patient to surgery, around 3% to 43% of patients experience their recurrence following lumbar decompressive surgery [7]. A surgical procedure, whether it is a microdiscectomy or other minimally invasive procedures, is accompanied by certain risks and a necessary period of recovery. This often, in the case of slower progress, can be associated with unemployment and depression [6,7].

This high and variable rate of poor surgical outcomes encourages the use of modern non-invasive methods, which promise to achieve similar or better results without the need for a long postoperative recovery. Non-surgical spinal decompression represents a direct alternative to surgical treatment. This non-surgical approach enables the application of a precise dose of decompression force directly to the affected segment and thereby reduces the degree of herniation and pressure on the spinal nerve. During the entire therapy, the patient lies on a special couch fixed by a belt system and positioned using movable segments. Thereby, the decompression force created by the control unit responsible for precise dosing is applied precisely to the herniated segment. Treatment can be provided alone or in combination with another method of physical therapy. A possible supplement to this therapy is high-intensity peripheral repetitive magnetic field (RPMS) stimulation, which enables through a strong magnetic field to target deep structures, increase their blood supply and reduce spasticity and pain [8,9].

While the effectiveness of non-surgical spinal decompression has been confirmed by several studies in patients with lumbar disc herniation, the impact of RPMS on low back pain has not been investigated to such an extent

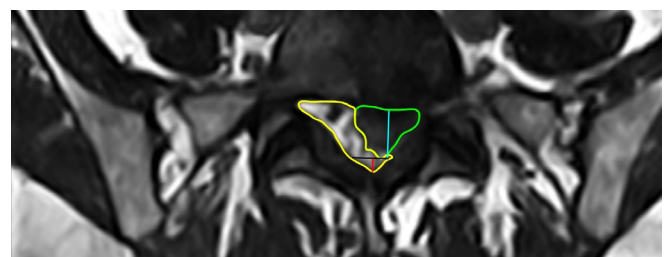
[8, 10-16]. Clinical evidence describing the effect of the combination of both approaches is completely lacking. The present case study aims to describe a protocol combining non-surgical spinal decompression and RPMS during twelve sessions and to present the results achieved in a patient with a significant herniation in the lumbar region accompanied by sciatica symptoms. It is important to outline the promising outcomes of a non-invasive approach, even in patients who, by current standards, are predisposed for surgery.

## Case Report

A 49-year-old female recreational kite surfer with a normal BMI (weight: 60 kg, height: 158 cm) doing a sedentary job as a secretary without any medical, traumatic or surgical background, complained of acute sciatic pain after intensive gardening. Intramuscular pharmacologic therapy remained without any effect, and two-week application of nonsteroidal anti-inflammatory drugs did not lead to significant improvement. The main symptoms were pain radiating along the L5 dermatome and a feeling of paresthesia along the back of the foot. The main limitation was the disability at work due to persistent pain while sitting, especially when sitting for a long time. The patient also reported frequent pain at night impairing the quality of sleep and the inability to perform sports or other leisure activities.

The physical examination revealed a positive straight leg raise test at 40° and 60° on the affected and unaffected limb, respectively. While the wassermann test was evaluated as negative for both sides, the slump test showed positivity. The Medical Research Council (MRC) Scale Muscle Strength evaluation showed a rating of 4/5 for hip extensors, flexors and abductors and knee and plantar flexors. Hip adductors, knee extensors and dorsal flexors and extensors were rated 5/5. During the initial session, the patient rated pain as 9/10 using visual analog scale (VAS) and disability as 68% using a self-assessed Oswestry disability questionnaire.

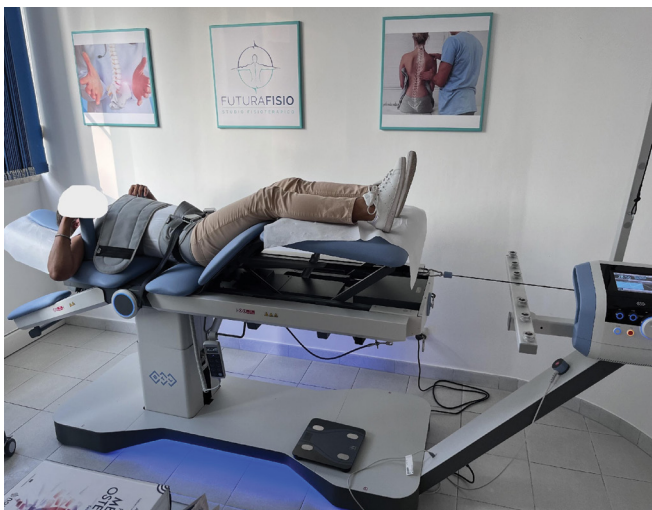Suspected lumbar disc herniation was confirmed by MRI, which showed a profound herniation in the L5 region. The length and area of the herniation as well as the length and area of the canal were further evaluated by MRI software (MicroDicom DICOM Viewer 2023.3 x86). The values are



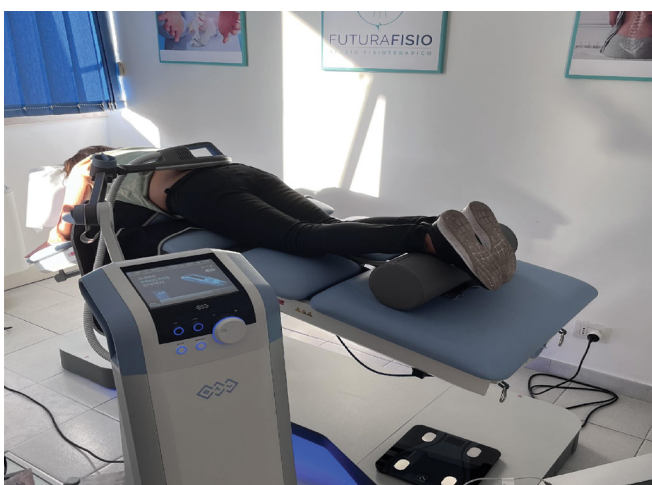**Figure 1:** Quantitative evaluation performed on obtained MRI images. The green area represents the disc area while the yellow area represents the channel area. The red and blue curves show the canal and herniated disc length, respectively.

shown in Table 1 and demonstrate that this was a herniation of a large extent, by common standards indicating the patient for surgery. The measurement methodology is shown and described in Figure 1 [17].

The treating physiotherapist decided to choose a non-invasive program consisting of 10 sessions combining non-surgical spinal decompression and RPMS. The patient underwent the session during a six-week treatment course, after which she was asked to fill in the questionnaires again and undergo an MRI examination. Non-surgical spinal decompression therapy (BTL Industries, Ltd.) was performed in the supine position for 30 min with a setting of 60-65 kg (Figure 2). Similarly, the RPMS (BTL Industries, Ltd.) treatment took place on a couch, but in a prone position for 12 minutes (Figure 3).



**Figure 2:** Application of non-surgical spinal decompression during a treatment program aimed at lumbar disc herniation.

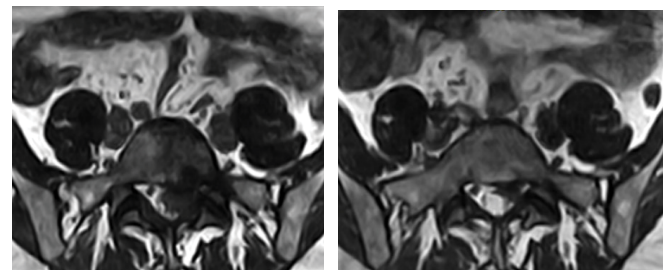


**Figure 3:** Course of RPMS therapy in the course of a combined protocol for the relief of sciatica symptoms due to lumbar disc herniation.

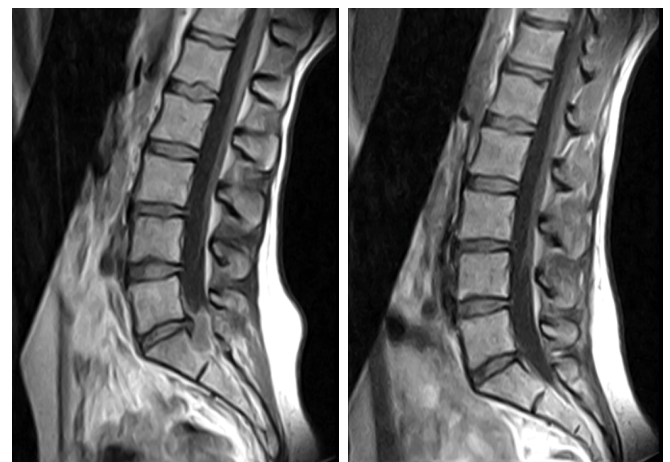
In the course of the non-invasive treatment program, the patient experienced significant improvement in terms of pain and disability. During the last visit, she rated pain at 1.5/10 and disability at 14%, which means almost complete recovery and return to daily activities. This improvement was also confirmed by the quantitative evaluation of the MRI images taken, when a significant decrease in the length and area of the herniation and, on the contrary, an increase in the area of the canal was observed (Table 1). Mutual comparison of images taken before and after completion of the treatment program is offered in Figures 4 and 5, respectively.

**Table 1:** Quantitative evaluation of MRI images and comparison between the images taken before and after completion of the treatment program.

	Before	After
<b>Disc herniation length (mm)</b>	10.3	7.27
<b>Herniation area (mm<sup>2</sup>)</b>	147.3	105.07
<b>Canal length (mm)</b>	2.9	6.25
<b>Canal area (mm<sup>2</sup>)</b>	157.76	244.52



**Figure 4:** Comparison of MRI T2 weighted images in the axial plane taken during the initial visit (left) and after completion of the treatment program (right).



**Figure 5:** Comparison of MRI T1 weighted images in the sagittal plane taken during the initial visit (left) and after completion of the treatment program (right). Disc herniation was diagnosed at the L5 level.



## Discussion

The present case study showed the possible benefit of a non-invasive combined protocol in the treatment of lumbar disc herniation in the extent indicating patient for surgery. The positive effect of non-surgical spinal decompression on the lumbar herniation has already been demonstrated by several studies, but due to the complexity of the MRI examination, most of them are based on subjective evaluations of the symptoms [10-14]. Current medical practice prescribes an MRI examination only in the case of considering surgical intervention and therefore images are not part of the standard examination package. However, there are also a couple of studies that evaluated the effect of non-surgical spinal decompression on lumbar disc herniation quantitatively using MRI [15,16]. But these too mostly focus on herniations of small to medium size, not exceeding the supposed threshold of 6 mm. This threshold for predisposing a patient to surgical intervention was established by Carragee and Kim as early as 1997 and has since been challenged by several studies [18]. Nevertheless, there is a generally valid theory that the size of the herniation according to MRI correlates with the outcomes of the surgical procedure [19]. Successful non-invasive therapy in a patient with a herniation exceeding 1 cm can therefore be considered relatively unique.

The degree of improvement achieved by non-invasive means can be caused by a suitably chosen combination of physical methods. While non-surgical spinal decompression provides mechanical manipulation within the impaired segment, which enables the herniated material to be pushed out of the spinal canal space, RPMS enables the stimulation of deep muscle structures, reducing their spasticity, improving blood circulation and reducing pain in the given area [8]. Both methods are non-invasive, applied lying down through clothing and are very well tolerated. The application of both technologies took a total of 42 minutes, which, together with the setup, made the entire session less than an hour. Compared to the recovery and possible risks associated with surgery, this combined approach can be considered very promising, even in patients with a herniated disc of a large extent.

The great effect of conventional therapy could also be given by a positive individual response - the patient who was investigated in this case study was in good physical condition, middle-aged and showed acute sciatica symptoms, which generally have a good prognosis in treatment with non-invasive methods [20]. Thus, general conclusions cannot be drawn from the results of present study, it only indicates the possible potential of non-invasive methods in the treatment of a condition that normally requires invasive intervention. For the purposes of evaluating the effectiveness of the combined protocol, it is desirable to conduct research involving a larger sample size.

Despite the mentioned shortcomings, this case study can serve as inspiration for patients concerned about surgery and looking for non-invasive alternatives, as well as for professionals in the field of physiotherapy expanding their knowledge and possibilities in the treatment of herniated discs.

## Conclusion

This case study presents the successful non-invasive treatment of a 49-year-old female patient with a herniated disc in the lumbar region exceeding 1 cm, both in terms of suppression of sciatica symptoms and improvement of MRI findings. The combination of non-surgical spinal decompression and RPMS therapy thus represents a promise for patients who are indicated for surgical intervention, but prefer an alternative non-invasive treatment without the risk of side effects and the need for post-operative recovery.

## A Declaration of Conflict of Interest statement

The author declares that he has no known competing financial interests or personal relationships that could have appeared to influence the work reported in this paper.

## Informed consent statement

Due to the retrospective nature and the fact that this is a case report describing the results obtained during a routine rehabilitation protocol, ethics committee approval was not required. The patient was informed about the published data and agreed to their publication by signing the written consent form.

## References

1. Wu A, March L, Zheng X, et al. Global low back pain prevalence and years lived with disability from 1990 to 2017: estimates from the Global Burden of Disease Study 2017. *Ann Transl Med* 8 (2020): 299.
2. Al Qaraghlhi MI, De Jesus O. Lumbar Disc Herniation. Accessed December 15, 2023. <https://www.ncbi.nlm.nih.gov/books/NBK560878/>
3. Dydyk AM, Ngnitewe Massa R, Mesfin FB. Disc Herniation. Accessed December 12, 2023. <https://www.ncbi.nlm.nih.gov/books/NBK441822/>
4. Disc Herniation. Accessed November 27, 2023. [https://www.physio-pedia.com/index.php?title=Disc\\_Herniation&oldid=346421](https://www.physio-pedia.com/index.php?title=Disc_Herniation&oldid=346421).
5. Gugliotta M, da Costa BR, Dabis E, et al. Surgical versus conservative treatment for lumbar disc herniation: a prospective cohort study. *BMJ open* 6 (2016): e012938.
6. Jacobs WC, van Tulder M, Arts M, et al. Surgery versus conservative management of sciatica due to a lumbar herniated disc: a systematic review. *Eur Spine J* 20 (2011): 513-522.

7. Aljawadi A, Sethi G, Islam A, et al. Sciatica Presentations and Predictors of Poor Outcomes Following Surgical Decompression of Herniated Lumbar Discs: A Review Article. *Cureus* 12 (2020): e11605.
8. Lim YH, Song JM, Choi EH, et al. Effects of Repetitive Peripheral Magnetic Stimulation on Patients With Acute Low Back Pain: A Pilot Study. *Ann Rehabil Med* 42 (2018): 229-238.
9. Kanjanapanang N, Chang KV. Peripheral Magnetic Stimulation. Accessed November 24, 2023. <https://www.ncbi.nlm.nih.gov/books/NBK526087/>
10. Ma SY, Kim HD. The Efficacy of Spinal Decompression via DRX3000 Combined with a Spinal Mobilization and a Lumbar Stabilization Exercise Program for Patients with Discogenic Low Back Pain. *J Phys Ther Sci* 22 (2010): 345-354.
11. Amjad F, Mohseni-Bandpei M.A, Gilani SA, et al. Effects of non-surgical decompression therapy in addition to routine physical therapy on pain, range of motion, endurance, functional disability and quality of life versus routine physical therapy alone in patients with lumbar radiculopathy; a randomized controlled trial. *BMC Musculoskelet Disord* 23 (2022): 255.
12. Carmona YC, Martin AT. Impact of Spinal Decompression Therapy on Disability, Pain and Mental Health in Patients with Lumbar Disc Herniation. *Spine Res* 9 (2023): 001.
13. Narkeesh A, Divya M. Efficacy of Spinal Decompression Therapy in Individuals with Lumbar Disc Herniation - A Randomized Controlled Trial. *Physical Medicine & Rehabilitation Journal* 4 (2022):131.
14. Kasimovich KN, Dmitrievich SE. Outcomes of Non-Surgical Spinal Decompression Therapy in Patients with a Herniated Disc Across Different Age Groups. *J Nov Physiother* 13 (2023): 564.
15. Choi E, Gil HY, Ju J, et al. Effect of Nonsurgical Spinal Decompression on Intensity of Pain and Herniated Disc Volume in Subacute Lumbar Herniated Disc. *Int J Clin Pract* (2022): 6343837.
16. Demirel A, Yorubulut M, Ergun N. Regression of Lumbar Disc Herniation by Physiotherapy. Does Non-surgical Spinal Decompression Therapy Make a Difference? Double-blind Randomized Controlled Trial. *J Back Musculoskelet Rehabil* 1 (2017): 1015-1022.
17. Gupta A, Upadhyaya S, Yeung CM, et al. Does Size Matter? An Analysis of the Effect of Lumbar Disc Herniation Size on the Success of Nonoperative Treatment. *Global Spine J* 10 (2020): 881-887.
18. Carragee EJ, Kim DH. A prospective analysis of magnetic resonance imaging findings in patients with sciatica and lumbar disc herniation. Correlation of outcomes with disc fragment and canal morphology. *Spine* 22 (1997): 1650-1660.
19. En'wezoh DC, Leonard DA, Schoenfeld AJ, et al. Relationship between size of disc and early postoperative outcomes after lumbar discectomy. *Arch Orthop Trauma Surg* 137 (2017): 805-811.
20. Koes BW, van Tulder MW, Peul WC. Diagnosis and treatment of sciatica. *BMJ (Clinical research ed.)* 334 (2007): 1313-1317.