

Case Report

Hemosuccus Pancreaticus: Mysterious Cause of Gastrointestinal Bleeding and Pain

Rajesh Yadav, Raviraj Sudhakar Rao Chavan *

Department of General Surgery, Bombay Hospital Institute of Medical Sciences, Mumbai, India

*Corresponding author: Rajesh Yadav, Consultant, Bombay Hospital Institute of Medical Sciences, Mumbai, India

Received: 10 April 2021; Accepted: 16 April 2021; Published: 27 August 2021

Citation: Raviraj Sudhakar Rao Chavan, Rajesh Yadav. Hemosuccus Pancreaticus: Mysterious Cause of Gastrointestinal Bleeding and Pain. Journal of Surgery and Research 4 (2021): 455-458.

Abstract

Hemosuccus pancreaticus is a very rare but severe form of upper gastrointestinal hemorrhage. The most common etiology is peripancreatic pseudoaneurysm secondary to chronic pancreatitis. These pseudoaneurysms may either bleed intra abdominally following rupture or may erode into the adjacent hollow viscera and manifest as gastrointestinal bleeding. Pseudoaneurysms rarely communicate with the pancreatic duct and bleeding occurs from the ampulla of Vater in the form of hemosuccus pancreaticus. Due to the rarity of gastroduodenal artery pseudoaneurysms, most of the current literature consists of case reports. Limited knowledge about the disease causes diagnostic difficulty

Keywords: Pancreatitis; Pseudoaneurysm; Gastrointestinal bleeding; Hemosuccus Pancreaticus;

Gastroduodenal artery; Superior pancreaticoduodenal artery

1. Introduction

Hemosuccus pancreaticus is an unusual cause of gastrointestinal bleeding [1]. It usually occurs as a complication of chronic or acute pancreatitis, with bleeding from a pseudoaneurysm arising from the peripancreatic arteries [2,3]. Splenic, gastroduodenal and pancreaticoduodenal arteries are the vessels commonly involved while pseudoaneurysm of left gastric artery are less common [4]. We present a rare case of hemosuccus pancreaticus (hemoductal pancreatitis) in a patient with alcoholic chronic pancreatitis. Since patient couldn't afford angioembolisation and having chronic pain for which he wanted definitive management so we decided to

undergo emergency surgery.

2. Case Report

A Forty two-year-old male patient with alcohol induced chronic pancreatitis, who had been medically managed for the past few months, presented having had a sudden onset of epigastric pain and melena for the previous 48 hours. He also complained of dyspepsia, anorexia and steatorrhoea since 2 months. 12 hours after admission he had multiple episodes of hematemesis. On examination, he had pallor, tachycardia of 110 per min and blood pressure of 100/60 mmHg. His abdominal examination did not reveal any abnormal findings except for epigastric and periumbilical tenderness. Nasogastric tube aspiration showed altered blood. His the serum hemoglobin was 6 g/dl (reference range: 14-18 g/dl). Two units of PCV transfused. An emergent esophagogastroduodenoscopy and colonoscopy was performed which was almost normal. A computerized tomography scan of the abdomen and pelvis plus CT angiography showed chronic calcific pancreatitis with small pseudoaneurysms noted along proximal and distal segments of gastroduodenal artery with acute haemorrhage in pancreatic duct suggesting hemosuccus Pancreaticus. Due to the ongoing bleeding and hemodynamic instability, the patient had to undergo emergency surgery. During intraoperative period, we injected needle with syringe in pancreatic duct, blood was aspirated. Then we opened pancreatic duct:calculi, blood clots and fresh bleed noted. Gastroduodenal artery identified and ligated at base. Superior pancreaticoduodenal artery was eroded from calculi, which was underrun with 5-0 prolene. Lateral pancreaticojejunostomy was done. Surgery was uneventful. Post operative period was uneventful. No fresh episodes of hematemesis and malena were noted.

3. Discussion

Chronic and acute pancreatitis are the most common cause of pseudoaneurysms arising from the peripancreatic arteries [3]. Pseudoaneurysms may result from either auto digestion of the peripancreatic artery or erosion of a pseudocyst into the artery and conversion of its cavity into a pseudoaneurysm [3,5]. The splenic artery is the most common artery involved (60-65%) followed in decreasing order of frequency by gastroduodenal (20-25%), pancreaticoduodenal (10-15%), hepatic (5-10%) and left gastric arteries (2-5%) [6-9]. The bleeding may manifest itself as hemosuccus pancreaticus or wirsungorrhoea (bleeding into the pancreatic duct), upper or lower gastrointestinal hemorrhage due to erosion into adjacent hollow viscus, intraabdominal hemorrhage or as a sudden increase in the size of the pseudocyst [1,3,6]. Ruptured or bleeding pseudoaneurysms are associated with a mortality rate of 12-57% [6]. Although angiography is the gold standard for diagnosis and for characterizing the exact anatomical site, the pseudoaneurysm can invariably be demonstrated on a contrast enhanced CT scan [10]. In addition, the characteristic “to and fro sign” and bidirectional flow at the pseudoaneurysm neck may be demonstrated on ultrasound Doppler and can be diagnosed [11]. However, a thrombus inside the pseudoaneurysm and adjacent bowel gas often result in false negative findings on ultrasound Doppler and should not preclude a contrast-enhanced CT scan. In hemodynamically stable patients, angio-embolization gives good immediate results in 67-100% of cases [4,12-14]. However, in patients who are hemodynamically unstable, where angiography is unavailable or embolization is unsuccessful, emergency surgery is required. In addition, surgery is required in 17-37% patients with recurrent bleeding

following embolization [15]. Also in the present case, contrast-enhanced CT demonstrated the pseudoaneurysm arising from the gastroduodenal artery. However, due to some technical issues for embolisation and hemodynamic instability, the patient had to undergo emergency surgery. The choice between simple ligation of the offending vessel and excision of the pseudoaneurysm is largely dictated by anatomical location, previous surgery, associated pathology, hemodynamic stability and the risk of re-bleeding and procedure-related mortality [6,7,9,14]. Deroofing the pseudoaneurysm, preferably after proximal and distal arterial control, evacuation of the clot and suture ligation of the affected artery is

recommended at surgery. Most surgical series have a documented success rate of 70-85% with mortality rates of 20-25% and rebleeding rates of 0-5% [6,7,9,14]. Thus, pseudoaneurysms of peripancreatic arteries may arise as a complication of acute or chronic pancreatitis and can result in life threatening hemorrhage. A diagnosis can usually be made on contrast-enhanced CT scan. Angiography provides the exact localization and the possibility of embolization which, in a significant number of patients, might be adequate treatment. Surgery is required when embolization fails or is unavailable, when there is recurrence of bleeding after embolization or in case of hemodynamic instability.

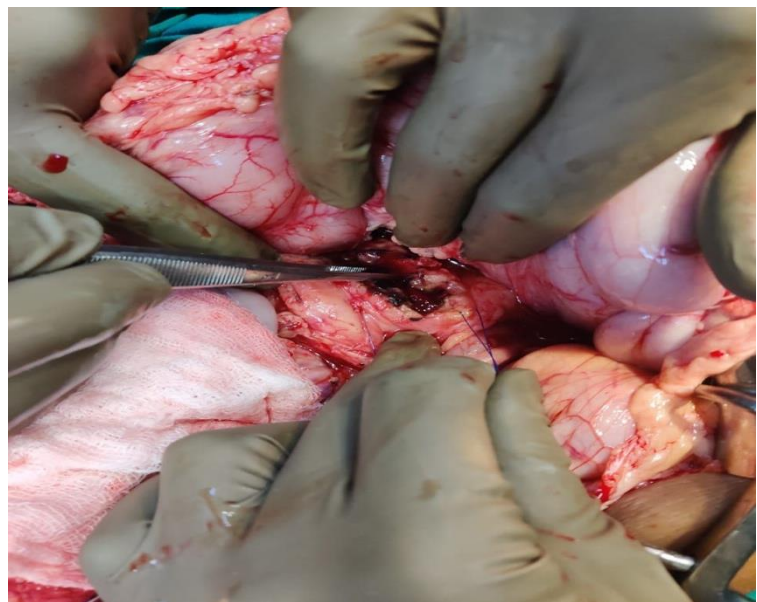
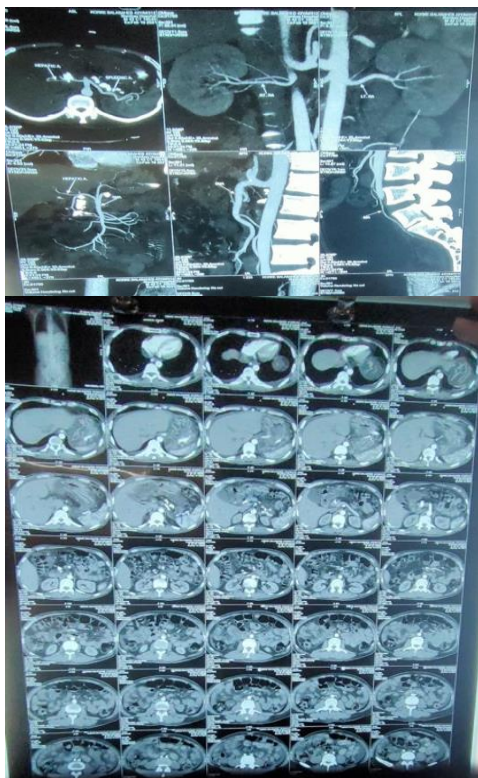

Figure 1: Inerop picture showing blood clots in pancreatic duct

References

1. Bivins BA, Schatello CR, Chuang VP, et al. Haemosuccus pancreaticus (haemoductal pancreatitis). *Arch Surg* 113 (1978): 751-753.
2. Cahow CE, Gusberg RJ, Gottlieb LJ. Gastrointestinal haemorrhage from pseudoaneurysm in pancreatic pseudocysts. *Am J Surg* 145 (1983): 534-541.
3. Maus TP. Pseudoaneurysm haemorrhage as a complication of pancreatitis. *Mayo Clin Proc* 68 (1993): 895-896.
4. Stabile BE, Wilson SE, Debas HT. Reduced mortality from bleeding pseudocysts and pseudoaneurysms caused by pancreatitis. *Arch Surg* 118 (1983): 45-51.
5. Stanley JC, Frey CF, Miller TA, et al. Major arterial haemorrhage - A complication of pancreatic pseudocysts and chronic pancreatitis. *Arch Surg* 111 (1976): 435-440.
6. Bender JS, Bouwman DL, Levison MA, Weaver DW. Pseudocysts and pseudoaneurysms: surgical strategy. *Pancreas* 10 (1995): 143-147.
7. Heath DI, Reid AW, Murray WR. Bleeding pseudocysts and pseudoaneurysms in chronic pancreatitis. *Br J Surg* 79 (1992): 281.
8. Smith RE, Fontanez-Garcia D, Plavsic BM. Gastrointestinal case of the day. Pseudoaneurysm of the left gastric artery as a complication of acute pancreatitis. *Radiographics* 19 (1999): 1390-1392.
9. Negi SS, Sachdev AK, Bhojwani R, et al. Experience of surgical management of pseudoaneurysms of branches of the coeliac axis in a North Indian hospital. *Trop Gastroenterol* 23 (2002): 97- 100.
10. Burke JW, Erickson SJ, Kellum CD, et al. Pseudoaneurysms complicating chronic pancreatitis: detection with CT. *Radiology* 161 (1986): 447-450.
11. Kahn LA, Kamen C, McNamara MP. Variable color Doppler appearance in pancreatitis. *AJR Am J Roentgenol* 162 (1994): 187-188.
12. Mandel SR, Jagues PF, Mauro MA, et al. Nonoperative management of peripancreatic arterial aneurysms: a ten year experience. *Ann Surg* 205 (1987): 126-128.
13. Gambiez LP, Ernst OJ, Merlier OA, et al. Arterial embolization for bleeding pseudocysts complicating chronic pancreatitis. *Arch Surg* 132 (1997): 1016-1021.
14. Waltman AC, Lucra PR, Athanasoulis CA, et al. Massive arterial haemorrhage in patients with pancreatitis. Complimentary roles of surgery and trans catheter arterial embolization. *Arch Surg* 121 (1986): 439-443.
15. Boudghene F, Hermine L, Bigot JM. Arterial complications of pancreatitis: diagnostic and therapeutic aspects in 104 cases. *J Vasc Interv Radiol* 4 (1993): 551-558.



This article is an open access article distributed under the terms and conditions of the [Creative Commons Attribution \(CC-BY\) license 4.0](https://creativecommons.org/licenses/by/4.0/)