


**Case Report**

## Femur Neck Fracture in a Patient with Klippel-Trenaunay Syndrome- Case Report

Fabio Seiji Mazzi Yamaguchi<sup>1\*</sup>, Leandro Ejnisman<sup>1</sup>, Julio Parente<sup>1</sup>, Daniel Teixeira Bussius<sup>1</sup>, Bruno Alves Rudelli<sup>1</sup>, Helder de Souza Miyhara<sup>1</sup>, Henrique Melo de Campos Gurgel<sup>1</sup>

### Abstract

Klippel-Trenaunay Syndrome (KTS) is a rare congenital disorder characterized by a triad of capillary malformation with port-wine stain, varicose veins, or venous malformation of the lower limbs, and bony and soft tissue hypertrophy. In this case report, we present the case of a 47-year-old woman who was diagnosed with KTS in her left lower limb at the age of 22. She was admitted to the Hip Group Ambulatory at the Hospital das Clinicas of Sao Paulo, Brazil, due to osteoarthritis in her left hip joint caused by KTS. The patient suffered a Garden 4 left femoral neck fracture after falling from a standing position. Based on imaging, physical examination, and vascular evaluation, our initial surgical plan was Total Hip Arthroplasty (THA) with bone graft and acetabular cage via the posterior approach. However, due to significant blood loss, hemodynamic instability, and the presence of large vessels close to the acetabulum, we decided to abort the initial plan of THA and instead opted for Resection Arthroplasty of Girdlestone. KTS is a challenge for orthopedic surgeons and requires a multidisciplinary evaluation. Patients with KTS who undergo THA require a radiologic study of malformations to choose an appropriate surgical approach, despite the high risk of bleeding.

**Keywords:** Femur Neck Fracture; Klippel-Trenaunay Syndrome; Osteoarthritis

### Introduction

Klippel-Trenaunay Syndrome (KTS) is a rare congenital disorder that was first reported in 1900 by two French physicians, Maurice Klippel and Paul Trenaunay. This disease is characterized by a triad of symptoms: (1) capillary malformation with a port-wine stain, (2) varicose veins or venous malformation of the lower limbs, and (3) bony and soft tissue hypertrophy. The diagnosis is typically made using Doppler ultrasound studies of the lower limb vessels and by identifying at least two of these three signs [1]. KTS affects both sexes equally and can affect any part of the body, but the lower extremities are the most commonly affected [2]. The *PIK3CA* gene (ID:5290) encodes the phosphoinositide 3-kinase enzyme, which plays a crucial role in intracellular signaling and cell proliferation. In some cases of KTS, mutations have been detected in the *PIK3CA* gene. These mutations result in a gain of gene function, which leads to tissue hypertrophy in the bone, soft tissue, and blood vessels [3]. This syndrome can present with a wide range of clinical symptoms, ranging from cosmetic complaints to severe disability. While leg-length discrepancy is common in adulthood, it is rarely present at birth [1,2]. There are few articles on KTS-associated fractures, and none specifically on femoral neck fractures in young patients.

#### Affiliation:

Hip Surgery Department of Institute of Orthopedics and Traumatology, University of São Paulo, São Paulo, Brazil

#### \*Corresponding Author

Fabio Seiji Mazzi Yamaguchi, Institute of Orthopedics and Traumatology, University of São Paulo, São Paulo, Brazil.

**Citation:** Fabio Seiji Mazzi Yamaguchi, Leandro Ejnisman, Julio Parente, Daniel Teixeira Bussius, Bruno Alves Rudelli, Helder de Souza Miyhara, Henrique Melo de Campos Gurgel. Femur Neck Fracture in a Patient with Klippel-Trenaunay Syndrome- Case Report. Archives of Clinical and Medical Case Reports. 7 (2023): 120-123.

**Received:** February 22, 2023

**Accepted:** March 02, 2023

**Published:** March 16, 2023

### Case Presentation

The patient, a 47-year-old woman, was diagnosed with KTS at the age of 22. She was admitted to the Hip Group ambulatory at Hospital das Clinicas in São Paulo due to osteoarthritis in her left hip joint, which was caused by KTS in her left lower limb. The patient exhibits mild hypertrophy in the left lower limb, varicose veins in the anterolateral aspect of the left thigh, and a port-wine stain in the anterior aspect of the left leg (see Figure 1). Radiography of the pelvis showed advanced osteoarthritis of the left hip joint with Otto pelvis and a segmental defect of the acetabular roof (see Figure 2).

The patient presented with a 3.0 cm left leg length discrepancy and had been experiencing severe daily pain in her left hip joint for the past three years. She had been undergoing conservative treatment for osteoarthritis of the hip joint, as there was a high risk of complications associated with performing a Total Hip Replacement due to her KTS. However, in July 2021, the patient fell from a standing position and suffered direct trauma to her left hip joint, resulting in a left femur neck fracture (see Figure 3). A radiological investigation was performed due to vascular malformation (see Figure 4). Based on the images, physical examination, and vascular evaluation, our surgical team planned a Total Hip Arthroplasty with bone graft and acetabular cage using a posterior approach.

The patient's preoperative laboratory results were as follows: Hemoglobin: 12.2 g/dL, Hematocrit: 36.7%, White blood cells: 10,550/ $\mu$ L, INR (International normalized ratio): 0.95, and fibrinogen: 365 mg/mL. Due to the high risk of bleeding, we have decided to use general anesthesia with invasive monitoring. During the superficial dissection, an unusual amount of bleeding was encountered in the region. However, with careful cauterization, hemostasis was achieved. Despite a rigorous tenotomy of external rotators and capsulotomy, significant arterial and venous bleeding occurred from multiple sites. This led to hemodynamic instability in the patient, necessitating the introduction of norepinephrine

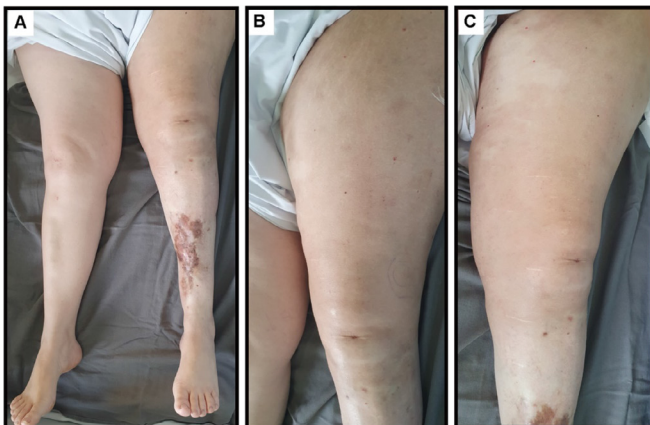


Figure 1: clinical images of affected limb.

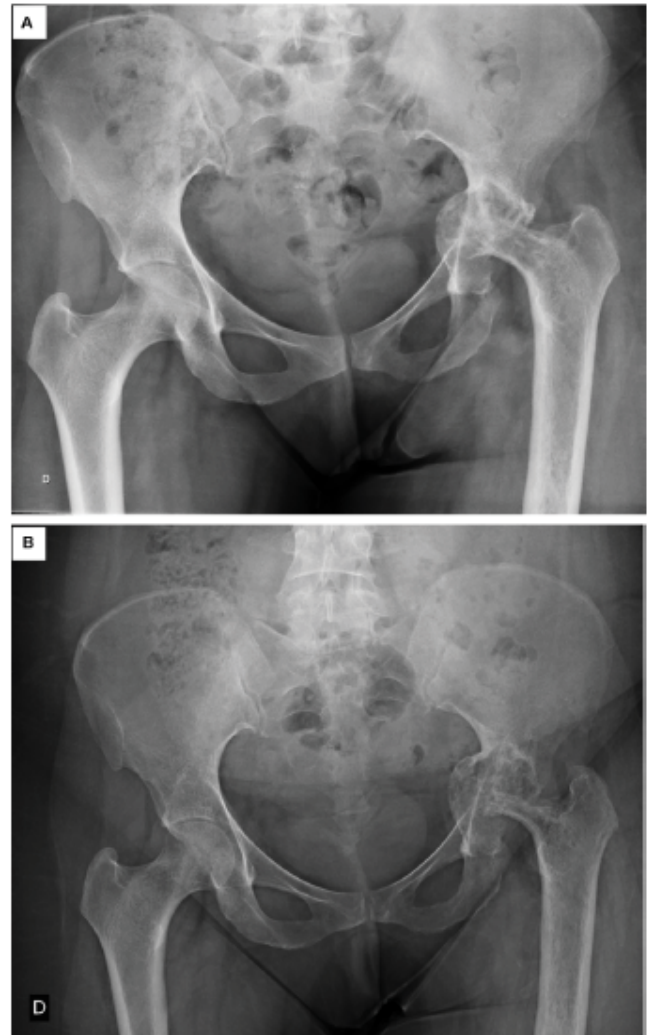


Figure 2: radiographic progression of the left hip joint (A:2014, B: 2019).

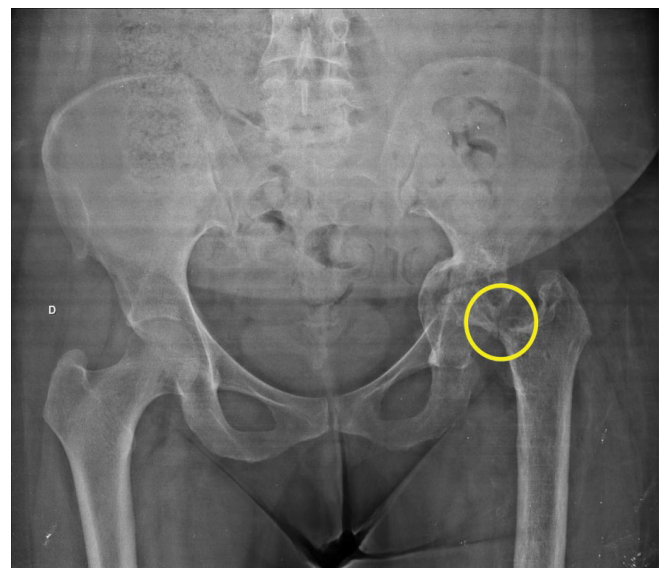
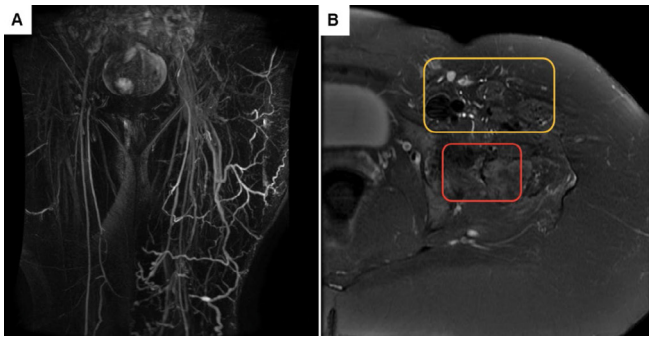
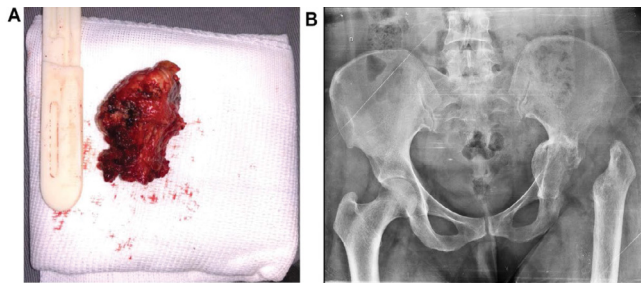


Figure 3: pelvis radiography AP. Left femur neck fracture-yellow circle.



**Figure 4:** MRI of the left hip joint. A: Angio-MRI of the limb (an expressive increase of collateral circulation in the left thigh); B: MRI of the left hip joint, fracture (red square), and relationship with vessels (yellow square).



**Figure 5:** femoral head and post-op radiography. A: femoral; B: left hip joint radiography.

and the transfusion of red blood cell concentrates. Following hemostasis, a femur neck osteotomy and femur head removal were performed. Bleeding was observed from the bone marrow and large vessels located on the inferior and medial aspect of the acetabulum. Due to the significant blood loss, hemodynamic instability, and the presence of large vessels in close proximity to the acetabulum, it was decided to abort the initial plan of THA and instead proceed with a Resection Arthroplasty of Girdlestone (Figure 5).

The surgery lasted for 4 hours, during which there was a blood loss of 4 liters. Intraoperatively, the patient received 4.1 liters of crystalloids and 5 units of red blood cell concentrates. Postoperatively, the patient's hemoglobin level was 7.1 g/dL, hematocrit was 20.8%, white blood cell count was 8,500/ $\mu$ L, INR was 1.06, and fibrinogen was 175 mg/dL.

## Discussion

In the literature, there is limited information on KTS patients with femur fractures, and no information is available on those with femoral neck fractures in young patients. KTS is a rare and complex disease that is characterized by venous varicosities, capillary malformations, and limb hypertrophy. As it often affects the extremities and bones, patients with KTS frequently require evaluation by an orthopedic surgeon. A previous study reported that 64% of KTS patients presented with orthopedic complaints, including

7% with osteopenia/osteoporosis and 6% with pathological fractures [4]. Femoral neck fractures in young patients are rare, accounting for approximately 3% of cases, and are typically caused by high-energy trauma mechanisms and displaced fracture patterns. In this particular case, there was observed progressive reabsorption of the femoral neck bone (as seen in figure 2), which was likely due to an increase in blood flow in the proximal femur. This may have contributed to the pathological femoral neck fracture by a low-energy trauma mechanism in a young woman. There is a consensus on the surgical treatment of femoral neck fractures in young adults, which involves using internal fixation methods such as compression screws and dynamic hip screws as the first option. However, in this case, due to the patient's prior osteoarthritis in the left hip joint, the initial surgical plan was THA. THA is a challenging surgical procedure for patients with KTS, and the choice of surgical approach depends on image studies and physical examination. As described in this case report, despite images showing a vascular malformation on the anterolateral aspect of the thigh, the posterior approach resulted in significant bleeding during both superficial and deep dissections. Schoch et al. reported on surgical complications of THA in KTS patients, including perioperative bleeding, disseminated intravascular coagulation (DIC), and wound complications. Therefore, the procedure carries a high risk of bleeding and may require massive transfusion [4]. According to Spencer et al., THA is considered a last resort treatment due to the numerous potential post-operative complications. A preoperative evaluation must include an assessment for coagulopathy, which is common in KTS patients. Bleeding from bony surfaces can also impact cementation results by reducing cement interdigitation in the cancellous bone and impairing implant stability. In addition, KTS patients are at a higher risk of infections, wound healing issues, and other surgical complications [5]. Garcia-Juarez et al. demonstrated that preoperative evaluation with imaging methods is critical for the safe performance of THA surgery. An ideal imaging study should combine doppler ultrasound and Magnetic Resonance Imaging (MRI) to analyze intraosseous vascularization. This approach provides surgeons with a greater understanding of the patient's anatomy, enabling them to make more informed decisions about the indication and performance of the procedure [6]. Zhu et al. also suggest that MRI is a more appropriate imaging test because it can reveal differences in soft tissue and vascular malformations [7]. Cirstoiu et al. observed significant bleeding after capsulotomy, with high blood loss and bleeding coming from the bone marrow after osteotomy [8]. On the other hand, Willis-Owen et al. were able to successfully perform THA by conducting arteriography to evaluate the vascular malformation. To reduce intraoperative bleeding, they opted for preoperative embolization of arteriovenous shunting, which decreases bleeding without modifying bone quality [9].



## Conclusion

KTS presents a challenge for orthopedic surgeons and requires a multi-disciplinary evaluation. Patients with KTS who undergo THA require prior radiologic studies to identify malformations and determine an appropriate surgical approach. Despite this, THA in KTS patients carries a high risk of bleeding. Therefore, preoperative embolization should be considered as a possible intervention to control intraoperative bleeding and facilitate the successful completion of THA. In our case report, due to massive intraoperative bleeding, we decided to abort the planned THA and instead perform a Girdlestone resection arthroplasty. During the 10 months of follow-up, the patient has shown good progress, is able to walk with the assistance of a cane, and reports only mild pain in the left hip joint that is controlled with usual analgesics.

## References

1. Wang SK, Drucker NA, Gupta AK, et al. Diagnosis and management of the venous malformations of Klippel-Trénaunay syndrome. *Journal of Vascular Surgery: Venous and Lymphatic Disorders* 5 (2017).
2. Abdel Razek AAK. Imaging findings of Klippel-Trenaunay syndrome. *Journal of Computer Assisted Tomography* 43 (2019).
3. John PR. Klippel-Trenaunay Syndrome. *Techniques in Vascular and Interventional Radiology* 22 (2019): 100634.
4. Schoch JJ, Nguyen H, Schoch BS, et al. Orthopaedic diagnoses in patients with klippel-trenaunay syndrome. *J Child Orthop* 13 (2019).
5. Spencer SA, Sorger JI. Orthopedic issues in vascular anomalies. *Seminars in Pediatric Surgery* 29 (2020).
6. García-Juárez JD, Tohen-Bienvenu A, Jiménez-Cabuto IC, et al. Artroplastía total de cadera en el síndrome de Klippel-Trenaunay. Reporte de un caso y revisión de la literatura. *Acta ortopédica mexicana* 25 (2011).
7. Zhu W, Xie K, Yang J, et al. Diagnosis of Klippel-Trenaunay syndrome and extensive heterotopic ossification in a patient with a femoral fracture: A case report and literature review. *BMC Musculoskeletal Disorders* 21 (2020).
8. Cirstoiu C, Cretu B, Sandu C, et al. Failed Attempt of Total Hip Arthroplasty in a Patient with Klippel-Trenaunay Syndrome: A Case Report. *JBJS Case Connector* 9 (2019).
9. Willis-Owen C, Cobb J. Total hip arthroplasty in Klippel-Trenaunay syndrome. *Annals of the Royal College of Surgeons of England* 90 (2008): 6-8.