

## Case Report

# Delayed Diagnosis and Treatment of Simultaneous Bilateral Adnexal Torsion

Misgav Rottenstreich, Reut Rotem, Fayez Khatib, Shunit Armon, Orna Reichman a, Sorina Grisaru-Granovsky, Hen Y Sela \*

Department of Obstetrics and Gynecology, Hebrew University Medical School, Jerusalem, Israel

\***Corresponding author:** Hen Y Sela, Department of Obstetrics and Gynecology, Shaare Zedek Medical Center, 12 Bayit Street, Jerusalem, 91031, Israel, Telephone: +972-2-655-5562; Fax: +972-2-666-6053; E-mail: [hysela@szmc.org.il](mailto:hysela@szmc.org.il)

**Received:** 28 August 2020; **Accepted:** 04 September 2020; **Published:** 09 September 2020

**Citation:** Misgav Rottenstreich, Reut Rotem, Fayez Khatib, Shunit Armon, Orna Reichman a, Sorina Grisaru-Granovsky, Hen Y Sela. Delayed Diagnosis and Treatment of Simultaneous Bilateral Adnexal Torsion. Journal of Women's Health and Development 3 (2020): 376-378.

### Abstract

Adnexal torsion (AT) is a gynecologic emergency that requires prompt diagnosis and treatment to relieve patient symptoms and to achieve viable adnexa. We present a case that resulted in delayed diagnosis and treatment of simultaneous bilateral adnexal torsion most following the use of ART. Our delayed diagnosing resulted likely from the identical appearance of the ovaries on ultrasound and alternative diagnosis of ovarian hyperstimulation syndrome, an awareness to this rare phenomenon of simultaneous bilateral adnexal torsion might have helped to perform the surgery earlier.

**Keywords:** Adnexal torsion; Ovarian hyperstimulation syndrome; Ultrasound; Advanced reproductive technology

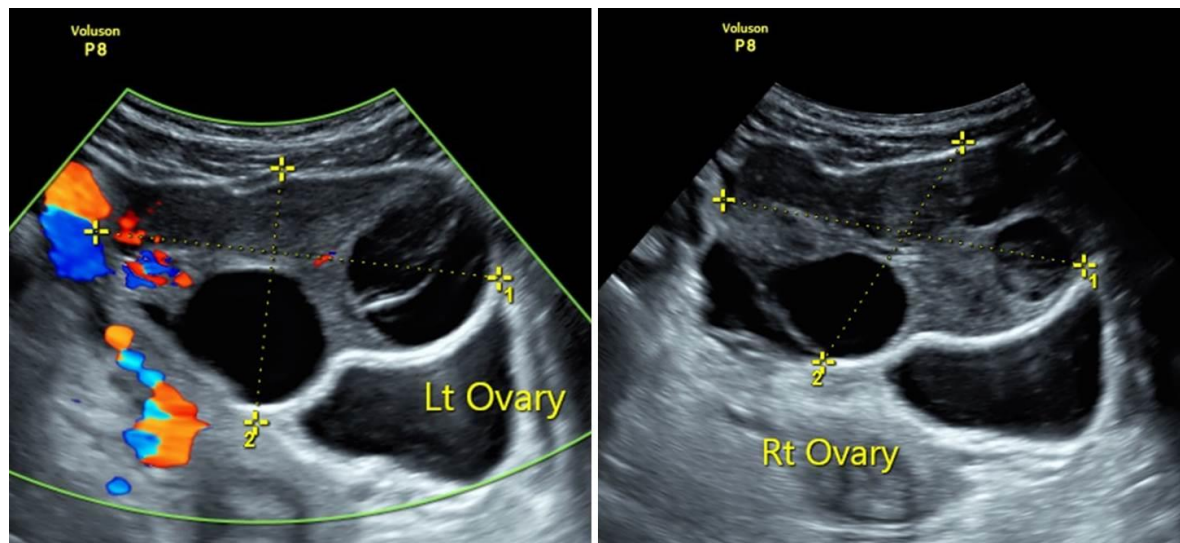
### 1. Introduction

Adnexal torsion (AT) is a gynecologic emergency accounting for 2.7 percent of emergency surgeries [1]. In 86-95% of women with AT ovarian mass exist, making it the primary risk factor for AT [2]. Ovulation induction and In Vitro Fertilization (IVF) occasionally results in the formation of large ovarian follicular cysts and, in some patients,

massive ovarian enlargement due to hyperstimulation. Adnexal torsion may occur in women with ovarian hyperstimulation syndrome (OHSS) in up to 8% [3]. Prompt diagnosis and treatment of AT is of importance, in order to relieve patient symptoms and to have better chances of achieving viable adnexa for future fertility and quality of life.

## 2. Case Report

We present a case of a 41-years old G1P1 that was referred to our medical center eight days following an oocyte retrieval (9 oocytes) and one week after single blastocyst transfer due to lower abdominal pain, nausea and vomiting. Upon exam, her vital signs were normal; the abdomen was tender with rebound tenderness mostly on the left side. A trans-abdominal ultrasound revealed enlarged ovaries (right ovary measuring  $8.7 \times 6.2$  cm; left ovary  $6.5 \times 4.9$  cm) both had multiple peripheral follicles. In the Cul de sac there was mild amount of free fluid. Blood flow (arterial and venous) to both ovaries appeared normal and both ovaries appeared roughly the same (Image 1). Initial laboratory tests showed leukocytosis of  $20.8 \times 10^3/uL$ , hematocrit of 35.4% and normal electrolytes. Initial impression was that it was a case of OHSS so she was treated with intravenous fluids and upon clinical improvement was discharged with a diagnosis of OHSS. She returned to the hospital within 12 hours with the same complains, her exam, vital signs, laboratory results and ultrasound exam were the same however due to an increasing abdominal pain we decided to proceed with a diagnostic laparoscopy. At the laparoscopy both ovaries were twisted, the right ovary was twisted twice and enlarged to 8 cm, the left ovary was twisted once and enlarged to 6 cm; it showed hemorrhagic and congestive changes, but no necrosis. The ovaries were untwisted and the large follicles were aspirated.



**Figure 1:** Transabdominal ultrasound revealed enlarged bilateral ovaries with multiple peripheral follicles. Doppler ultrasonography demonstrated normal ovarian blood flow.

### **3. Discussion**

Pre-operative diagnosis of AT is often difficult to reach because of its non-specific symptoms and signs and the absence of precise laboratory and imaging findings. The Radiological Society of North America (RSNA) recommends to compare the gray-scale US appearance and flow of the contralateral ovary to aid significantly in diagnosis of ovarian torsion and that this should be performed at every examination [4]. Indeed Asynchronous bilateral AT may occur, however simultaneous bilateral AT is very rare [5]. We believe that the delayed diagnosis and treatment (12 hours) in our case stems from the lack of the classic ultrasound signs of AT : the presence of enlarged edematous ovary as oppose to contralateral normal ovary given the simultaneous bilateral torsion and the absence of normal contralateral adnexa to compare an AT, we misdiagnosed her as suffering from OHSS. Awareness to this possible but rare presentation of bilateral AT and lack of classical US signs should be kept in mind especially in the case of women undergoing artificial reproductive technologies.

### **Acknowledgements**

Patient consent form has been completed and signed by the patient.

### **Disclosure Statement**

All authors have no conflict of interest or benefit that has arisen from the direct applications this research to disclose.

### **Funding**

None of the authors have any direct or indirect financial incentive associated with publishing the article.

### **References**

1. Hibbard LT. Adnexal torsion. *Am J Obstet Gynecol* 152 (1985): 456-461.
2. White M, Stella J. Ovarian torsion: 10-year perspective. *Emerg Med Australas* 17 (2005): 231-237.
3. Gorkemli H, Camus M, Clasen K. Adnexal torsion after gonadotrophin ovulation induction for IVF or ICSI and its conservative treatment. *Arch Gynecol Obstet* 267 (2002): 4-6.
4. Chang HC, Bhatt S, Dogra VS. Pearls and pitfalls in diagnosis of ovarian torsion. *Radiographics* 28 (2008): 1355-1368.
5. Wafa Al Omari, Saad Ghazal-Aswad, Islam H Sidky, Maha Khalid Al Bassam. Ovarian salvage in bilaterally complicated severe ovarian hyperstimulation syndrome. *Fertil Steril* 96 (2011): e77-e79.



This article is an open access article distributed under the terms and conditions of the [Creative Commons Attribution \(CC-BY\) license 4.0](https://creativecommons.org/licenses/by/4.0/)