

Research Article

Cholesterol Granulomas Nasal Polyp in Sphenoethmoid Recess: An Atypical Aspect in a Common Lesion

Sara Aversa^{1,2,3*}, Bargiacchi Lavinia², Linda Ricci³, Veronica Sorrentino^{1,2}, Romano Antonio⁴, Vincenzo Petrozza^{2,5*}, Cristiana Bellan³

¹Department of Anatomical, Histological, Forensic and Orthopaedic Sciences, Section of Human Anatomy, Sapienza University of Rome, Rome, Italy.

²Pathology Unit, I.C.O.T. Hospital, Latina, Italy.

³Department of Medical Biotechnologies, University of Siena, Siena, Pathology Unit, Siena, Italy

⁴U.O.C Otolaryngology, University Hospital "Le Scotte" Siena, Italy

⁵Department of Medico-Surgical Sciences and Biotechnologies, Sapienza University, Rome, Italy .

***Corresponding Author(s):** Sara Aversa, Department of Anatomical, Histological, Forensic and Orthopaedic Sciences, Section of Human Anatomy, Sapienza University of Rome, Rome, Italy (1), Pathology Unit, I.C.O.T. Hospital, Latina, Italy (2), E-mail: sara.aversa@uniroma1.it ; sara.aversas@gmail.com

Vincenzo Petrozza, Department of Medico-Surgical Sciences and Biotechnologies, Sapienza University, Rome, Italy (5). Pathology Unit, I.C.O.T. Hospital, Latina, Italy (2). E-mail: vincenzo.petrozza@uniroma1.it

Received: 09 January 2021; **Accepted:** 22 January 2021; **Published:** 22 February 2021

Citation: Sara Aversa, Bargiacchi Lavinia, Linda Ricci, Veronica Sorrentino, Romano Antonio, Vincenzo Petrozza, Cristiana Bellan. Cholesterol Granulomas Nasal Polyp in Sphenoethmoid Recess: An Atypical Aspect in a Common Lesion. Journal of Surgery and Research 4 (2021): 68-71.

Abstract

Nasal polyp is a non neoplastic lesion of the respiratory mucosa. In few cases, it can be possible to detect the presence of cholesterolgranuloma. We present the case of a 55 year-old patient affected by a nasal lesion, localized in sphenoethmoidal recess, with

particular microscopic feature and a review of the literature.

Keywords: Nasal polyp; Lesion; Cholesterolgranuloma

1. Introduction

Nasal polyp is a benign lesion of the respiratory mucosa.

This condition is present in 40% of the population and it has a chronic course in about 4% of cases [1]. They are more common in adults in particular localized in ethmoid sinuses [2]. It has been observed that the pediatric population frequently presents this pathology with a preference for the antrocoanal localization [3]. Cholesterolgranuloma in the paranasal sinuses is rare. Here we report the case of a patient with a sphenoethmoidal localization of the lesion with a particular microscopic feature. A review of the literature follows.

2. Material and Methods

A 55-year-old patient presented to clinicians observation complaining difficulty breathing and a lost sense of smell. Remote pathological anamnesis detected an allergy to grasses. The patient first

underwent nasal endoscopy, which did not detect any alteration. Subsequently CT scan of the facial mass was carried out revealing an isolated neoformation of the right nasal fossa of the sphenoethmoid recess. It is decided to proceed with the surgical removal of the lesion. Surgical Sample consisted of a fragment polypoid in shape with a maximum diameter of 2,3 cm. The neoformation showed a smooth fleshy, gray-pink surface. At microscopic examination the lesion was composed by myxoid stroma with increased vasculature (Figure 1) covered by respiratory epithelium admixed with glandular structures. Into edematous lamina propria, weak lymphocytic infiltration, constituting of small lymphocytes, could be observed. At the apex of the lesion a gigantocellular granulomatous inflammatory reaction was appreciated, surrounding optically empty spaces reachable by cholesterol needles (Figure 2). Final diagnosis was: Paranasal sinus cholesterol granuloma.

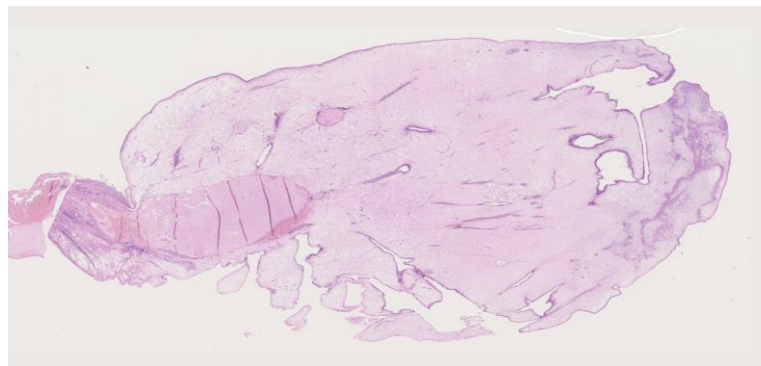


Figure 1: An entire section of the nasal polyp that allow to show its histologic architecture. Hematoxilin eosin 1,25 X.

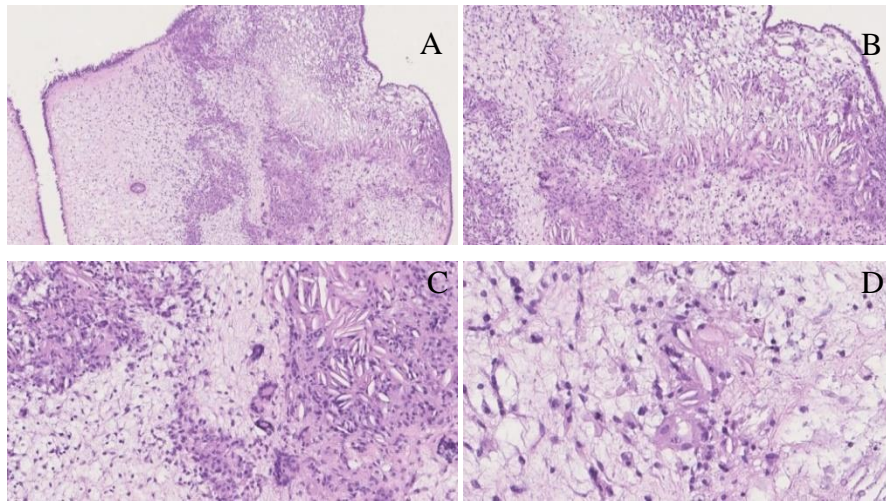


Figure 2: (A) Hematoxylin eosin 5 X; (B) Hematoxylin eosin 10 X; (C) Hematoxylin eosin 20 X; (D) Hematoxylin eosin 40 X.

3. Discussion and Conclusion

Nasal polyps are soft, painless, noncancerous growths on the lining of nasal passages or sinuses [4]. They are associated with a persistent local inflammation condition due to asthma, recurring infection, allergies, drug sensitivity or certain immune disorders [5]. Groups of nasal polyps or larger ones cause a swelling of the nasal mucosa and a reduction of the respiratory space and lead to breathing problems such as progressive nasal obstruction, frontal headache, alteration of smell. Small nasal polyps may not cause symptoms [6]. They appear as translucent mass that histologically shows edematous lamina propria with variable inflammatory infiltrate including eosinophils [7]. Different subtypes of this lesion have been described: angiectatic (angiomatic), cystic, edematous, fibrous, glandular. Our case is characterized by the presence of cholesterol needles at the top of the lesion. Macrophage cells rupture or necrosis cause cholesterol release, which crystallizes in the form of empty needle shapes. There is granulation tissue with foreign body type giant cells that surround the needles created by the cholesterol crystals. Repeated bleeding that occurs in a mucosa degenerated by chronic

inflammation could explain the onset of such lesions. Correlation between the neof ormation size and dimension of paranasal sinus concerned can be an important parameter to consider. An exophytic lesion localized in a “small chamber” lined with a non-functioning mucosa is not optimally vascularized. This could allow a local microtrauma which favors the precipitation of cholesterol with the formation of crystals [8]. The site of the reaction (the “peak” of neof ormation) favors both the hypothesis: the most peripheral portion of a lesion is the site that most easily undergoes degeneration. Cholesterol granulomas have been found mainly in the neof ormations of the frontal and maxillary sinuses [9]. Few cases of nasal lesions with granulomatous reaction have been described in ethmoidal and antrocoanal sinus [2, 3]. At the current state there is no difference in diagnostic tests and therapy regarding cholesterol granulomatous polyps [10, 11]. A histologic evaluation of the lesion is always advisable [12]. An accurate analysis can allow to highlight aspects that should be taken into consideration and may promote better overview of underlying disease.

References

1. Newton JR, Ah-See KW. A review of nasal polyposis. *Ther Clin Risk Manag* 4 (2008): 507-512.
2. Hellquist H, Lundgren J, Olofsson J. Cholesterol granuloma of the maxillary and frontal sinuses. *ORL J Otorhinolaryngol Relat Spec* 46 (1984): 153-158.
3. Alzahrani M, Morinière S, Duprez R, et al. Cholesterol granuloma of the maxillary sinus. *Rev Laryngol Otol Rhinol (Bord)* 131 (2010): 309-311.
4. Val-Bernal JF, Martino M, Castaneda-Curto N, et al. Cholesterol granuloma in an antrochoanal polyp. A rare lesion in children. *Rev Esp Patol* 51 (2018): 262-266.
5. Zhu LX, Kong WJ, Gong SS, et al. Twenty four cases of cholesterol granuloma of the paranasal sinuses. *Zhonghua Er Bi Yan Hou Tou Jing Wai Ke Za Zhi* 40 (2005): 517-520.
6. Schaberg MR, Shah GB, Evans JJ, et al. Concomitant transsphenoidal approach to the anterior skull base and endoscopic sinus surgery in patients with chronic rhinosinusitis. *J Neurol Surg B Skull Base* 74 (013): 241-246.
7. Sivasubramaniam R, Harvey RJ. How to Assess, Control, and Manage Uncontrolled CRS/Nasal Polyp Patients. *Curr Allergy Asthma Rep* 17 (2017): 58.
8. Yeh DH, Wong J, Hoffbauer S, et al. The utility of routine polyp histopathology after endoscopic sinus surgery. *Int Forum Allergy Rhinol* 4 (2014): 926-930.
9. DeConde AS, Mace JC, Levy JM, et al. Prevalence of polyp recurrence after endoscopic sinus surgery for chronic rhinosinusitis with nasal polyposis. *Laryngoscope* 127 (2017): 550-555.
10. Stevens WW, Schleimer RP, Kern RC. Chronic Rhinosinusitis with Nasal Polyps. *J Allergy Clin Immunol Pract* 4 (2016): 565-572.
11. Schleimer RP. Immunopathogenesis of Chronic Rhinosinusitis and Nasal Polyposis. *Annu Rev Pathol* 12 (2017): 331-357.
12. Shvili I, Hadar T, Shvero J, et al. Cholesterol granulomas in antrochoanal polyps: a clinicopathologic study. *Eur Arch Otorhinolaryngol* 262 (2005): 821-825.
13. Leon ME, Chavez C, Fyfe B, et al. Cholesterol granuloma of the maxillary sinus. *Arch Pathol Lab Med* 126 (2002): 217-219.



This article is an open access article distributed under the terms and conditions of the [Creative Commons Attribution \(CC-BY\) license 4.0](https://creativecommons.org/licenses/by/4.0/)