

Case Report

Bilateral Optic Disc Pit, Bilateral Iris Chorioretinal Coloboma and Unilateral Congenital Ptosis in a Person with Persistent Patent Ductus Arteriosus: A Rare Case with Review of Literatures

Raba Thapa MD, PhD*

Vitreoretina Specialist, Tilganga Institute of Ophthalmology, Kathmandu, Nepal

***Corresponding Author:** Dr. Raba Thapa MD, PhD, Associate Professor, National Academy of Medical Sciences, Vitreo-retinal Service, Tilganga Institute of Ophthalmology, Kathmandu, Nepal, Tel: 977-4493775; Fax: 977-1-4474937; E-mail: rabathapa@live.com

Received: 05 September 2019; **Accepted:** 02 October 2019; **Published:** 10 April 2020

Abstract

We report a 24 year old female presented with drooping of left eye upper lid since birth. Examination revealed left eye upper lid congenital ptosis, both eyes iris, chorioretinal coloboma and both eyes optic disc pit. Her medical records showed ligation of patent ductus arteriosus in her childhood. The ductus arteriosus closes soon after birth, but sometimes it fails to close leading to persistent patent ductus arteriosus. Optic disc pit, iris chorioretinal coloboma and congenital ptosis are among the rare congenital anomalies of eye. We report this case because of its rarity with review of literatures.

Keywords: Congenital ptosis; Chorioretinal coloboma; Iris coloboma; Optic disc pit; Patent ductus arteriosus

1. Introduction

During fetal life, most of the blood from pulmonary artery passes through the ductus arteriosus in to the aorta just below the origin of left subclavian artery. Normally, the ductus closes soon after birth. Persistence of patent ductus arteriosus (PDA) may be associated with other abnormalities and is much commoner in females. Small shunts are asymptomatic but large shunts may lead to retardation of growth and development. It can ultimately lead to cardiac failure. Most of the persistent ductus can be closed by percutaneous occlusion with the Rashkind umbrella or similar devices. Treatment with surgical division is also safe [1]. Iris and chorioretinal colobomas of the eye are caused by failure of the embryonic fissure of the optic cup to close during development. Typically, colobomas are located at the lower part of iris, chorioretina and optic disc. Chorioretinal coloboma can involve the part of optic disc and macula. Parents bring child for the poor vision, deviated eyes, small eyes or marked diminution of vision due to

retinal detachment [2, 3]. Congenital ptosis may be simple or complicated associated with other ocular anomalies. Ptosis covering the visual axis could lead to amblyopia if not corrected on time [4].

We report a case of PDA associated with multiple congenital anomalies of eye; unilateral congenital ptosis, both eyes iris, chorioretinal coloboma and optic disc pit for its rarity. This case can help the ophthalmologist and cardiologist for referral and cross-referral of such cases for prompt treatment to avoid the sight and life threatening complications.

2. Case Report

Twenty four years female was presented at Tilganga Institute of Ophthalmology with the chief complains of drooping of left eye lid since birth. She had no history of visual problems and other ocular problems. She had past history of Patent Ductus Arteriosus ligation 16 years back at the age of 8 years. On ocular examination, her best corrected visual acuity (BCVA) was 6/6 in both eyes (right eye: -0.25/-0.5 *90 degree, left eye: -0.25/-0.75*90 degree). There was congenital ptosis of left upper eye lid. The levator palpebral superioris (LPS) function was 7 mm, margin reflex distance (MRD1) was +1, and interpalpebral height was 8 mm in left eye. On anterior segment examination, she had bilateral iris coloboma located in the inferior part in both iris. Lens was normal. Fundus examination revealed bilateral optic disc pit and inferior chorioretinal coloboma not involving the optic disc and macula (Figure 1-3). Macula was normal. The rest of the retina was also flat. Eye lid revealed normal finding in right eye. Her intraocular pressure was 18 mmHg in both eyes on applanation tonometry. She was diagnosed as left eye upper lid congenital ptosis with bilateral iris and chorio-retinal coloboma with bilateral optic disc pit with refractive error. She was treated with barrage laser in both eyes for chorioretinal coloboma in 2015. She is in regular follow up since then and at her last follow up on July 2019, her BCVA was 6/6 and stable anterior and posterior segment findings. She was again advised for regular use of glass and follow up at six months interval or earlier as needed.

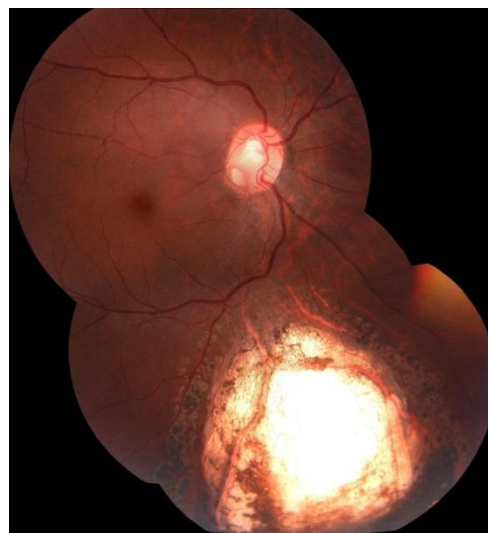

Figure 1: Right eye fundus photo showing chorioretinal coloboma and optic disc pit.

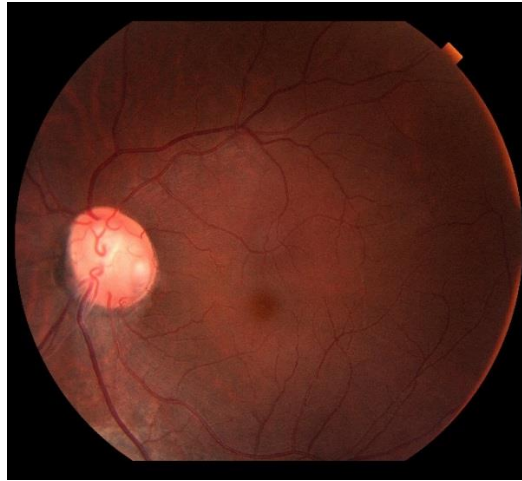


Figure 2: Left eye fundus photo showing optic disc pit.

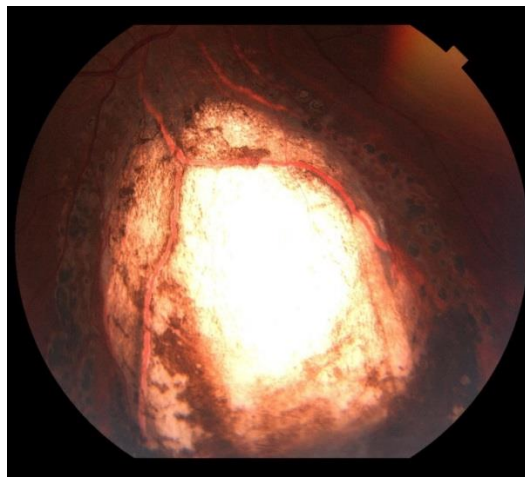


Figure 3: Left eye fundus photo showing chorioretinal coloboma.

3. Discussion

Congenital anomalies can involve any systems of the body. Careful suspicion and thorough evaluation is required to assess for its multisystem involvement. Here we report a case of multiple ocular congenital anomalies with congenital defect in heart. To the best of our knowledge, there are no typical reported cases of congenital ptosis, optic disc pit and iris, chorioretinal coloboma in a single person with PDA. Congenital ptosis can be simple or complicated. It may lead to occlusion amblyopia in severe cases [4]. Mild ptosis may be associated with Char syndrome, a rare genetic multiple congenital anomalies characterized by triad of PDA, facial dysmorphism and hand anomalies [3]. Although there was ptosis and PDA in our cases, there were absence of other abnormalities suggestive of Char syndrome. Optic disc pit may lead to serous detachment of macula. If not treated on time, it can lead to pigmentary changes in macula and macular scar leading to irreversible visual impairment. Treatment of such cases are also challenging [5, 6]. Iris and chorioretinal coloboma often coexist together [3]. Our cases was consistent with this findings. Chorioretinal coloboma may lead to retinal detachment. Hussain et al. reported bilateral

chorioretinal coloboma in 65.5% of his cases series and retinal detachment was found in 29.5% of the cases [7]. Presence of bilateral chorioretinal coloboma was consistent with the majority of their cases series. Uhumwangho and Jalali reported presence of retinal detachment in 17.6% and 87.2% of these cases had other ocular anomalies. The prevalence of retinal detachment among those who received prophylactic laser was 2.9% [8]. Absence of retinal detachment in the follow up of our patient could be because of the prior prophylactic laser in chorioretinal coloboma. Nakaura reported both presence of iris and chorioretinal coloboma in 24% of their cases series like in our case [9]. Ming et al reported colobomas and other ophthalmic anomalies in Kabuki Syndrome [10]. However, our cases had no other features suggestive of this syndrome. Our patient presented for the first time for cosmetic reason due to ptosis. Iris, chorioretinal coloboma and optic disc pit were diagnosed during her routine evaluation of anterior and posterior segment of eye. Furthermore, despite the presence of PDA diagnosis and its management at childhood, patient was not consulted for ophthalmic anomalies until the adolescent. So timely referral and systemic evaluation could help in timely detection of such congenital anomalies to save the sight and life.

4. Conclusion

Persistent ductus Arteriosus could be associated with multiple congenital anomalies of eye like congenital ptosis, iris, chorioretinal coloboma and optic disc pit. This case report highlights the importance of timely ocular evaluation for possible other congenital anomalies of eye in cases with PDA to save the sight. Cross referral has to be strengthened between ophthalmologist and cardiologist for timely diagnosis and treatment of life and sight threatening complications from these congenital disorders.

Funding

None

Conflict of Interest

None

References

1. Edwards CRW, Bouchier IAD, Haslett C. Davidson's Principles and Practice of Medicine. ELBS, 17th Edition (1995).
2. Sun M, Wei D, Lin H, et al. Coloboma of Iris and Choroid: Two Case Reports. HSOA J Ophthalmic Clin Res (2017): 034.
3. Satoda M, Pierpont ME, Diaz GA, et al. Char Syndrome, an Inherited Disorder With Patent Ductus Arteriosus, Maps to Chromosome 6p12-p21. Circulation (1999): 3036-3042.
4. Thapa R. Refractive error, Strabismus and Amblyopia in Congenital Ptosis. J Nepal Med Assoc (2010): 43-46.
5. Chatziralli I, Theodossiadis P, Theodossiadis GP. Optic disc pit maculopathy: current management strategies. Clinical Ophthalmol (2018): 1417-1422.

6. Moisseiev E, Joseph Moisseiev J, Anat Loewenstein A. Optic disc pit maculopathy: when and how to treat? A review of the pathogenesis and treatment options. *Int J Retin Vitre* (2015): 13.
7. Hussain RM, Abbey AM, Shah AR, et al. Chorioretinal Coloboma Complications: Retinal Detachment and Choroidal Neovascular Membrane. *J Ophthalmic Vis Res* (2017): 3-10.
8. Uhumwangho OM, Jalali S. Chorioretinal coloboma in a paediatric population. *Eye* (2014): 728-733.
9. Nakamura KM, Diehl NN, Mohney BG. Incidence, Ocular Findings and Systemic Associations of Ocular Coloboma: A Population-Based Study. *Arch Ophthalmol* (2011): 69-74.
10. Ming JE, Russell KL, Bason L, et al. Coloboma and other ophthalmologic anomalies in Kabuki syndrome: distinction from charge association. *Am J Med Genet A* (2003): 249-252.

Citation: Raba Thapa. Bilateral Optic Disc Pit, Bilateral Iris Chorioretinal Coloboma and Unilateral Congenital Ptosis in a Person with Persistent Patent Ductus Arteriosus: A Rare Case with Review of Literatures. *Archives of Clinical and Medical Case Reports* 4 (2020): 302-306.



This article is an open access article distributed under the terms and conditions of the [Creative Commons Attribution \(CC-BY\) license 4.0](https://creativecommons.org/licenses/by/4.0/)