

Case Report

Beta-Blocker Therapy for New-Onset Hypertension Following an Electrical Injury: A Case Report

Ho-Dong Yang BS¹, Donghoon Han MD^{1*}, Dong Geum Shin MD¹, Min-Kyung Kang MD, PhD¹, Jung Rae Cho MD, PhD¹, Seonghoon Choi MD¹, Jong-Wook Lee MD², Namho Lee, MD, PhD¹

¹Department of Internal Medicine, Cardiovascular Center, Kangnam Sacred Heart Hospital, Hallym University College of Medicine, Seoul, Korea

²Department of Plastic Surgery, Burn Center, Hangang Sacred Heart Hospital, Hallym University College of Medicine, Seoul, Korea

***Corresponding Author:** Dr. Donghoon Han MD, Clinical Associate Professor of Internal Medicine, Department of Internal Medicine, Cardiovascular Center, Hallym University, Kangnam Sacred Heart Hospital, Singil-ro, Yeongdeungpo-gu, 07441, Seoul, Korea, Tel: +82-10-9956-5535; E-mail: magnox@hallym.or.kr

Received: 11 March 2020; **Accepted:** 20 March 2020; **Published:** 27 April 2020

Abstract

Electrical injuries may occur in both home and workplace environments leading to cardiovascular complications, such as tachyarrhythmia, bradyarrhythmia, atrial fibrillation and myocardial injury. However, reports on electrical injury induced hypertension are rare. The choice of appropriate antihypertensive agents is therefore unclear. As described in this report, beta-blockers may be useful in hypertension induced by electrical injuries.

Keywords: Electrical injury; Hypertension; Beta-blocker; Cardiovascular complications; Skin graft

Abbreviations: ABI- Ankle-Brachial Index; ABPM- Ambulatory BP Monitoring; BP- Blood Pressure; FTSG- Full Thickness Skin Graft; LV- Left Ventricular; PCA- Patient-Controlled Analgesia; SR- Slow Release

1. Introduction

Electrical injury represents one of the most serious public health problems in both developing and developed countries, and occurs in both home and workplace settings [1, 2]. Electrical injuries may be caused by a wide range of factors, with a heterogeneous spectrum of resultant lesions, ranging from small skin burns to life-threatening injuries [1, 3, 4]. A previous study has reported that high voltage electrical burns induce changes in arterial function. The report documented that alterations in arterial function increased the risk of thrombosis and stenosis. However, there was no mention of resultant hypertension [5]. Here we describe a case of new-onset hypertension following an electrical injury that was treated with a beta-blocker.

2. Case Report

A 50-year-old man was admitted to our institute with high voltage (22,900 V) electrical injuries. He had sustained injuries to both hands; the total body surface area of the burn was 2% (Figure 1). Since the patient had lost consciousness for a few seconds at the time of injury, he did not notice the entrance and the exit of electricity. He was a never smoker and had no significant past medical history. The initial blood pressure (BP) on admission was 110/70 mmHg. The wounds on both the hands were dressed aseptically. However, active bleeding was noticed from the right index finger on admission day 13. Wound ligation was performed the next day, which arrested bleeding. Seven days later, a full thickness skin graft (FTSG) with debridement was performed on the right 3rd, 4th, and 5th fingers, and on the left 1st, 2nd, and 3rd fingers.

After surgery, the patient received patient-controlled analgesia (PCA) with a mixture of fentanyl citrate, ketamine, and ramosetron at doses of 2.355 mg, 1,000 mg and 0.6 mg. Following the skin graft, the patient's BP rose to a maximum of 160/100 mmHg, requiring cardiological consultation. Although the patient did not complain of any pain at the operated site, the cardiologist recommended active pain control with simultaneous investigations to identify the cause for BP elevation. The patient underwent testing with 24-hour ambulatory BP monitoring (ABPM) and an echocardiogram. Since he could not endure the pain of arm compression by the cuff during the 24-hour ABPM, the ankle-brachial index (ABI) was performed instead. The ABI was found to be in the normal range, but the blood pressure was elevated in each extremity (Figure 2). The echocardiogram did not demonstrate left ventricular (LV) hypertrophy or increased LV mass index. The patient was diagnosed as a case of new-onset hypertension. He was accordingly prescribed sustained release (SR) carvedilol (nonselective 3rd generation beta-blocker) at a dose of 8 mg once daily. One month after prescription of the medicine, although the patient's systolic BP dropped to 130~140 mmHg, the systolic BP intermittently rose to 150 mm Hg. The dose of carvedilol was accordingly increased to 16 mg, following which his BP was maintained in the normal range (Figure 3).

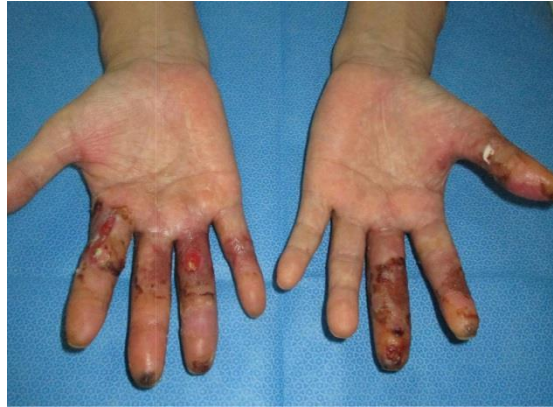

Figure 1: The patient’s hands injured by high-voltage electricity (before skin graft surgery).

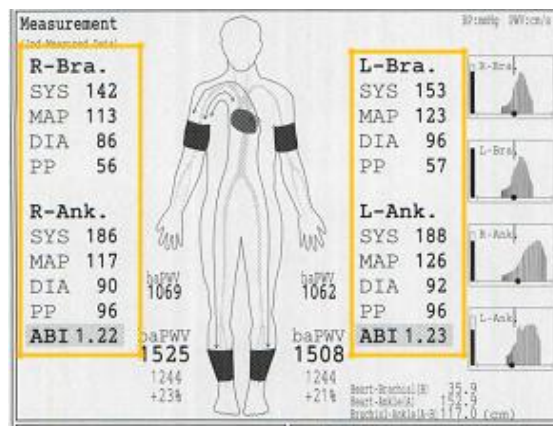


Figure 2: Ankle-Brachial Index (ABI) was performed instead of 24-hour ambulatory blood pressure (BP) monitoring. It showed elevated BP in all of the patient’s extremities (orange boxes).

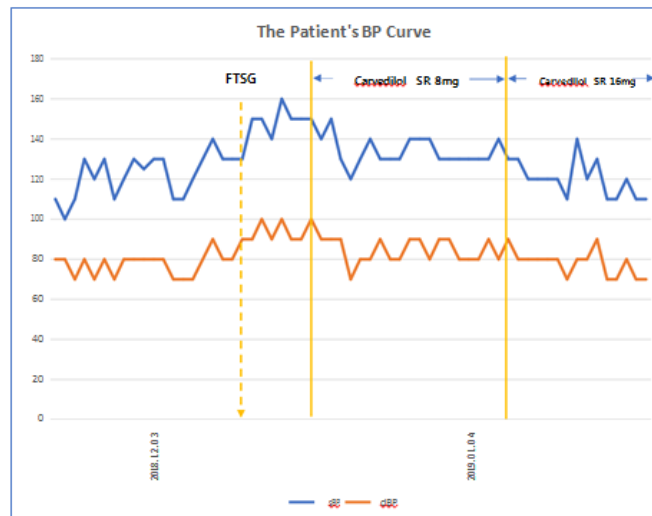


Figure 3: The patient’s BP curves. BP was elevated after the full thickness skin graft (FTSG). Following beta-blocker therapy (Carvedilol SR 8 mg), BP was maintained in the normal range.

3. Discussion

In this report, we described the case of a patient with new-onset hypertension after an electrical injury, with adequate control of blood pressure with a beta-blocker. Hypertension may be induced by pain in healthy individuals [6, 7]. In this case, pain control with analgesics could be helpful in controlling blood pressure [8]. In our case, we had initially speculated that the patient's blood pressure was probably elevated owing to post-operative physiological changes. However, since the patient's blood pressure was maintained at elevated levels after administration of opioids, the hypertension was unrelated to pain.

Beta-blockers no longer occupy the first-line status among the various classes of antihypertensive agents [9]. However, Arbabi et al. reported that beta-blocker therapy demonstrated beneficial outcomes in selected trauma patients. Traumas including burns induce increased protein catabolism, leading to the loss of body mass and muscle [10, 11]. Beta-blockers have also been found to decrease energy expenditure, and cardiac complications, reducing overall mortality [12, 13]. Although beta-blockers are not first-line antihypertensive agents in hypertension guidelines, we had chosen a beta-blocker for this patient based on the results of these previous studies.

In conclusion, it is essential to recognize that electrical injuries form a category of burn injuries which may induce hypertension. Hypertension induced by trauma, burn injuries, and surgical procedures is a distinct entity; beta-blocker therapy may be helpful in controlling blood pressure in these conditions. Further studies are necessary with regard to electrical injuries and their complications.

Declarations of Interest

None

Ethical Statement

The patient provided informed consent for publishing this data.

Acknowledgements

We extend our thanks to the patient for allowing this report.

Funding

None

Contributors

The work for this report has been supervised by D Han and N Lee; The patient was under the care of JW Lee, HD Yang, and D Han; The report was written by HD Yang and D Han; The report was reviewed by DG Shin, MK Kang, JR Cho, S Choi.

References

1. Koumbourlis AC. Electrical injuries. Crit Care Med 30 (2002): S424-S30.
2. Sun CF, Lv XX, Li YJ, et al. Epidemiological studies of electrical injuries in Shaanxi province of China: a retrospective report of 383 cases. Burns 38 (2012): 568-572.
3. Waldmann V, Narayanan K, Combes N, et al. Electrical cardiac injuries: current concepts and management Eur Heart J 39 (2018): 1459-1465.
4. Spies C, Trohman RG. Narrative review: electrocution and life-threatening electrical injuries. Ann Intern Med 145 (2006): 531-537.
5. Park KH, Park WJ, Kim MK, et al. Alterations in arterial function after high-voltage electrical injury. Crit Care 16 (2012): R25.
6. Bruehl S, Carlson CR, McCubbin JA. The relationship between pain sensitivity and blood pressure in normotensives. Pain 48 (1992): 463-467.
7. Bruehl S, Chung OY, Ward P, et al. The relationship between resting blood pressure and acute pain sensitivity in healthy normotensives and chronic back pain sufferers: the effects of opioid blockade. Pain 100 (2002): 191-201.
8. Chawla PS, Kochar MS. Effect of pain and nonsteroidal analgesics on blood pressure. WMJ 98 (1999): 22-25.
9. Ram CV. Beta-blockers in hypertension. Am J Cardiol 106 (2010): 1819-1825.
10. Monk DN, Plank LD, Franch-Arcas G, et al. Sequential changes in the metabolic response in critically injured patients during the first 25 days after blunt trauma. Ann Surg 223 (1996): 395-405.
11. Arbabi S, Ahrns KS, Wahl WL, et al. Beta-blocker use is associated with improved outcomes in adult burn patients. J Trauma 56 (2004): 265-269.
12. Minifee PK, Barrow RE, Abston S, et al. Improved myocardial oxygen utilization following propranolol infusion in adolescents with postburn hypermetabolism. J Pediatr. Surg 24 (1989): 806-810.
13. Reis SE, Feldman AH. Effect of atenolol on mortality and cardiovascular morbidity after noncardiac surgery. N Engl J Med 336 (1997): 1453-1454.

Citation: Ho-Dong Yang, Donghoon Han, Dong Geum Shin, Min-Kyung Kang, Jung Rae Cho, Seonghoon Choi, Jong-Wook Lee, Namho Lee. Beta-Blocker Therapy for New-Onset Hypertension Following an Electrical Injury: A Case Report. Archives of Clinical and Medical Case Reports 4 (2020): 307-311.



This article is an open access article distributed under the terms and conditions of the [Creative Commons Attribution \(CC-BY\) license 4.0](https://creativecommons.org/licenses/by/4.0/)