



## Anorectal Malformations with Visible Fistulas: Theoretical Substantiation of a New Version of the Cutback Procedure

Michael D. Levin, MD, PhD, DSc<sup>1,2\*</sup>

### Abstract

An analysis of the literature on the pathological physiology of anorectal malformations (ARM) with visible fistulas (perineal and vestibular) was performed. Histological, manometric, and radiological studies support the findings of Stephens and his followers that the bowel below the pubococcygeal line is a normally functioning anal canal, with an anterior displacement of the anus. The results of the cutback procedure, which completely preserves all elements of the anal canal, are distributed as follows (good - 85-90%; fair - 8-15%; poor  $\approx$  2%). After the introduction of posterior sagittal anorectoplasty (PSARP) without any scientific evidence, the ectopic anal canal was called a fistula, and pediatric surgeons began to destroy all elements of the anal canal. Applying the same method of evaluating long-term results after PSARP, we obtained the following results: - good -?; fair  $\approx$  40%; poor  $\approx$  60%). We have proposed a modification of the cutback procedure that differs in that, to simplify the management of postoperative patients and to avoid bougienage of the newly created anus, a tracheostomy tube with a diameter of 1.3–1.5 cm is inserted into the rectum. In the rectum, the balloon is inflated to fix the tube. Previously dissected skin, subcutaneous tissue, and the wall of the anal canal are sutured with single sutures from the ectopic anus to the tube. Conclusion: Analysis of studies on the pathophysiology of ARM with visible fistulas indicates the presence of a normally functioning anal canal. A great advantage of the cutback procedure compared to PSARP has been shown. We substantiated the modification of the cutback procedure, which facilitates the postoperative management of the patient, excludes bougienage of the newly created anus, and prevents the development of chronic constipation.

**Keywords:** Anorectal malformations; Perineal fistula; Vestibular fistula; Cutback procedure; Anal canal; New surgery

### Introduction

The concept of the pathological physiology of anorectal malformations (ARM) can be divided into two periods.

In 1953, Stephens proposed the concept of the pubococcygeal (P-C) line, which extends from the bottom of the pubic bone to the distal coccygeal vertebra. He demonstrated that this line corresponds to the location of the puborectalis muscle (PRM), situated between the rectum and the anal canal, playing a pivotal role in fecal retention. Cases where the blind end of the intestine is positioned above this line were categorized as high types, those at the P-C line level as intermediate types, and those below the P-C line as low types [1]. The Wingspread classification (1984) reflects this understanding

### Affiliation:

<sup>1</sup>Dorot. Medical Center for Rehabilitation and Geriatrics, Netanya, Israel

<sup>2</sup>Department of Pediatric Radiology, 1st State Hospital, Minsk, Belarus

### \*Corresponding author:

Michael D. Levin, Dorot. Medical Center for Rehabilitation and Geriatrics. Netanya, Israel.

**Citation:** Michael D. Levin. Anorectal Malformations with Visible Fistulas. Theoretical Substantiation of a New Version of the Cutback Procedure. *Journal of Pediatrics, Perinatology and Child Health*. 8 (2024): 210-216.

**Received:** September 19, 2024

**Accepted:** October 20, 2024

**Published:** November 11, 2024

of the pathological physiology of anorectal malformations (ARM). Accordingly, it was believed that if the intestine is situated caudally to the P-C line, the patient possesses an anal canal that must be preserved during surgery [2-6]. The low type encompassed anal stenosis, ARM with fistulas on the perineum and vaginal vestibule during that era.

The second stage, an ongoing phase, was initiated by the article from Pena and Devries [7]. This work introduced a posterior sagittal approach for correcting ARM through a pull-through procedure. Pena, lacking evidence, began asserting the absence of the anal canal in ARM cases [7]. The distal intestine, previously considered the anal canal in cases with visible fistulas, was now referred to as the fistula or rectal pouch, deemed incapable of performing anal canal functions. Consequently, Pena advocated for its removal and the lowering of the rectum into its place. These tactics are elucidated in an article co-authored with Levitt [8]. The subsequent discussions encompass scientific investigations into the pathological anatomy and physiology of ARMs with visible fistulas (perineal and vestibular).

### Pathological Anatomy and Physiology of ARMs with Visible Fistulas

**Histological Studies:** Alamovich et al. (cited from Duhamel) conducted investigations into the innervation of the normal internal anal sphincter (IAS). Their study revealed that the IAS lacks autonomic innervation, in contrast to the rest of the digestive tract [9]. In a study involving 3 newborn pigs with ARM, Lambrecht and Lierse observed that the proximal area of the fistulas in ARM exhibited many characteristics of a normal anal canal. They proposed that referring to a fistula as an ectopic anal canal is appropriate [10]. Notably, one study underscored the normal functionality of the IAS even in cases of high and intermediate types of ARMs [11]. Rintala et al. demonstrated that the distal rectum with a fistulous junction in ARM represents an ectopic location of the anal canal [12]. Uemura et al.'s [13] investigation led them to the conclusion: "The epithelial and ganglionic distribution was the same in the distal rectal end of the ARM and in the normal anal canal. The anal transition zone is the epithelial border between the rectum and the skin in the normal anal canal. Preservation of the anal transitional zone can reproduce the structure of the anal canal in ARM reconstruction" [13].

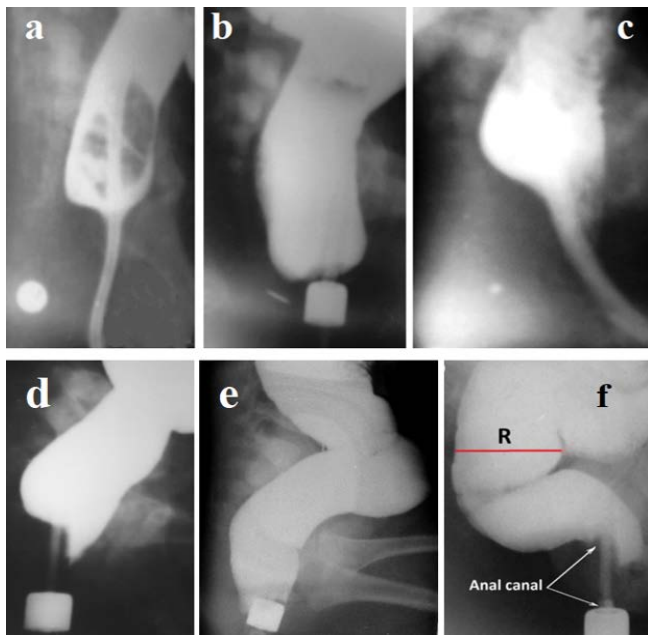
**Manometric Studies:** In 1877, Gowers discovered a decrease in pressure within the anal canal after introducing air into the rectum [14]. This reflex is known as the rectoanal inhibitory reflex. The pressure reduction in the upper part of the anal canal results from the relaxation of the IAS. Concurrently, there is an elevation in pressure in the lower part of the anal canal due to the contraction of the PRM and the external anal sphincter (EAS), which prevent rectal content leakage [15-17]. A rectal balloon was proposed for

the quantification of rectal pressure. Since then, the rectal balloon has become an integral component of this technique. For years, manometric studies were not conducted in ARM cases with visible fistulas due to the challenge of passing a rectal balloon through a narrow fistula. The abandonment of the rectal balloon enabled the execution of manometric studies in ARM cases with visible fistulas. A rapid injection of 50 cm<sup>3</sup> of air into the rectum was administered to generate high pressure in the rectum. The rectoanal inhibitory reflex was observed in all patients who successfully introduced a measuring device (endotracheal tube with an inflatable balloon) into the rectum. Basal pressure within the anal canal fell within the normal range [18]. Ruttensstock et al. [19] performed preoperative rectal manometry on recto-perineal or rectovestibular fistulas. They inserted a manometric device from the colostomy site and identified a rectoanal inhibitory reflex in all patients [19]. Ohama et al. [11] in a study involving 5 children with anorectal malformations (high type 2, intermediate type 3), conducted a preoperative manometric assessment of the rectal end using a probe inserted from the distal colostomy. The study revealed rhythmic activity in all patients and a positive reflex pressure drop during rectal distension in 4 [11]. Consequently, a manometric study in ARM cases with visible fistulas unveiled the functional attributes of the normal anal canal.

**X-ray Studies:** In patients with visible fistulas, the distal intestine remains in a closed state while at rest. It's length between the rectum and the anal fossa in children lacking significant megarectum is equivalent to the length of the normal anal canal (Figure 1a). During defecation, the anal canal widens to the dimensions of the rectum. In this instance, the caudal wall of the anal canal draws near to the anal dimple. The gap between the anal canal wall and the anal dimple spans from 2 to 5 mm, contingent upon age, equating the thickness of the skin and subcutaneous tissue (Figure 1b). Within a barium enema procedure, periodical penetration of the contrast agent into the upper section of the anal canal ahead of the enema tip is observable. In this moment, the posterior wall of the anal canal at this level is pressed against the enema tip due to the contracted PRM, representing the radiological counterpart of the rectoanal inhibitory reflex [18,20] (Figure 1c). In Figure 1, the anorectal zone physiology in ARM (a, b, c) is juxtaposed with normal physiology (d, e, f).

**Research Results:** Histological, manometric, and radiological studies indicate that patients with ARM with visible fistulas possess a normally functioning anal canal, ensuring prolonged fecal retention and effective defecation.

Normal basal pressure, a positive rectoanal inhibitory reflex, and consistent anal canal contraction are indicative of the IAS functioning normally [16-18,20]. The rectum unlike from the IAS serves to accumulate feces and cannot replace the IAS.



**Figure 1:** (a, b) Radiographs of the Same Girl with a Vestibular Fistula at Different Ages.

(a) At the age of 3 months, a catheter was inserted through the fistula into the rectum. Barium was introduced into the intestine via the catheter. The pushpin is situated near the anal dimple. The distal intestine, being as lengthy as the normal anal canal, constantly contracts around the catheter, preventing barium leakage.

(b) At 9 months of age, a broad opening of the anal canal occurred during a barium enema. The distance from the pushpin to the distal wall of the open anal canal measures 4 mm. Barium remains contained because the enema tip obstructs the narrow and rigid ectopic anus. The actual diameter of the marking on the enema tip is 1.6 cm. The rectal width measures 4.3 cm (maximum norm for children aged 1-3 years is 3.7 cm). Conclusion: anovestibular ectopy, megarectum.

(c) Barium was infused into the rectum using an endotracheal tube to gauge anal pressure. Barium penetration into the upper segment of the anal canal is observable ahead of the tube. This coincided with a pressure reduction in the upper part of the anal canal. The posterior wall of the anal canal is pressed against the tube due to the contracted PRM. After a few seconds, the anal canal contracted, propelling the barium into the rectum. This constitutes a characteristic x-ray representation of the rectoanal inhibitory reflex—namely, relaxation of the IAS accompanied by concurrent contraction of the PRM and the external anal sphincter (EAS), except for its subcutaneous part.

(d) Fecal retention phase in a healthy 1-month-old baby.

(e) Broad opening of the anal canal during attempt at bowel movements.

(f) at 12 years during IAS relaxation.

Prolonged and continuous contraction of the anal canal during periodic relaxation of the IAS signifies the proper functioning of the striated sphincters (EAS, PRM). The pressing of the posterior wall of the upper anal canal to the enema tip during IAS relaxation also supports the function of the PRM. The subcutaneous portion of the EAS is the only part that doesn't function in cases of ectopic anus. In

newborns, it spans about 2 mm, situated between the distal contour of the blindly ending IAS and the anal dimple. This segment constitutes (12%) of the 1.7 cm length of the newborn anal canal [21]. The subcutaneous part of the EAS briefly contracts during sudden increases in abdominal pressure, such as during coughing or rising from a seated position. However, the PRM and two larger sections of the EAS contract at the same time as the subcutaneous portion. Thus, the lack of function in the subcutaneous EAS portion does not impact stool retention quality [3-6, 20, 21].

No gaps exist within the pelvic floor muscles. The creation of a wide channel with a diameter matching that of the rectum during defecation using a liquid barium suspension demonstrates the proper function of the levator plates. Upon their contraction, a channel emerges within the pelvic floor muscles, considerably reducing resistance to feces movement during defecation [20].

The evidence provided concurs with the viewpoint of the European Consortium, which recently affirmed that “Based on current knowledge, the ‘fistula’ in ARM signifies an ectopic anal canal and should be preserved whenever possible to enhance the likelihood of fecal continence” [22]. An ectopic anus displaced anteriorly at the point of penetration through the subcutaneous tissue and skin inevitably forms a narrow, rigid ring, obstructing regular bowel passage. Depending on the diameter of this ring, a significant amount of feces accumulates in the rectum over time, leading to rectum and sigmoid colon expansion (megacolon). In severe cases, damage to the pelvic floor muscles, termed descending perineum syndrome, occurs [23]. Therefore, it is imperative to perform surgery on the child as early as possible, prior to the appearance of formed, i.e., dense stool.

### Comparison of Treatment Results after the Use of Cutback and PSARP

**Results after the Cutback Procedure:** The outcomes of the cutback procedure for low types of AWP in both boys and girls, based on the Wingspread classification, are outlined in Table 1. Ratings were deemed as “good” when normal fecal retention and absence of constipation were achieved, “fair” when patients required laxatives or enemas, and “poor” when fecal incontinence and/or uncontrollable constipation occurred [3, 24-26].

**Table 1:** Treatment Results after Cutback Procedure.

Authors	Good (%)	Fair (%)	Poor (%)
1. Ackroyd et al. [24]	98	0	2
2. Kyrklund et al. [25]	85	15	0
3. de la Fuente [26]	90	8	2
4. Nixon [3]	90	?	?

**Results after PSARP:** Stenström et al. [27] examined long-term outcomes following PSARP, with a median age of 8 years. They reported, “Among those with a perineal fistula, incontinence occurred in 42% of females and 10% of males, whereas constipation occurred in 62% of females and 35% of males” [27]. Levitt et al. [28] stated, “Children with ARM and a good prognosis for bowel control are at the greatest risk for severe constipation and its consequences” [28]. Lombardi et al. [29] demonstrated that constipation in cases of “low” ARM was present in 42-70% of instances. Notably, vestibular fistulas exhibited the highest rate of constipation (at least 61.4%) [29].

To enable a comparison of treatment outcomes, it is imperative to employ a uniform evaluation method. Consequently, we will employ the aforementioned method to assess the cutback procedure.

The cutback procedure has never yielded instances of fecal incontinence, even with the excision of the subcutaneous portion of the EAS. In contrast, after PSARP, incontinence occurred in 42% of females and 10% of males. Solely for this parameter, poor results were recorded in 42% of females and 10% of males following PSARP.

Constipation arises in no more than 15% of patients after the cutback procedure, but it tends to resolve over time [25]. Conversely, following PSARP, intense constipation emerges in 62% of females and 35% of males, often necessitating reoperations [30,31] and/or extended utilization of costly and intricate bowel management programs, incorporating high dosages of stimulant laxatives, the retrograde, or antegrade enemas [31,32]. Due to the absence of objective research methods employed by the authors of these articles, an accurate distribution of how many of the remaining cases correspond to fair or poor outcomes remains unattainable. What remains evident is that favorable results cannot manifest following the degradation of all sphincters involved in fecal retention and the muscles facilitating defecation. We compared the cutback procedure with PSARP. However, this comparison applicable to pull-through surgeries regardless of the approach, including anterior sagittal anorectoplasty and laparoscopy, given that the long-term outcomes of these methods exhibit minimal variance [33,34].

Comparing distinct treatments underscores the significant superiority of the cutback procedure over PSARP. This is because during pull-through surgeries, the anal canal undergoes destruction: the IAS is excised under the label of a “fistula”; the denervated and devascularized rectum is detached from the levator plates and repositioned onto the former IAS site; frequently, all segments of the EAS suffer damage, and the PRM is always crossed. Subsequently, not only do all muscles cease their participation in fecal retention and defecation, but they also become entirely bereft of

invisible nerve pathways essential for even partial restoration of function [35]. Detached levator plates no longer open the anal canal during attempted defecation. Fibrous tissue develops around the rectum. Consequently, post pull-through surgeries, an iatrogenic fistula devoid of function is produced, traversing through the pelvic floor. Should this fistula be broad, fecal incontinence predominates. In cases of narrow fistulas, severe constipation arises for the patient.

## Method of the Cutback Procedure

**The cutback procedure**, in contrast to the pull-through operation, entirely preserves the anal canal. As indicated by the outcomes of this procedure, intersecting the subcutaneous segment of the EAS never results in fecal incontinence. The objective of this operation is to incise the rigid ring to establish regular defecation. As noted by Nixon, “The simple cutback described by Denis Browne [36] is all that is necessary to enlarge the imperfect anus adequately for functional use. However, it’s crucial to supplement this with daily dilations for three months until the wound heals and regains its suppleness. For a newborn, a size 12 or 13 Hegar dilator is typically suitable, and when the mother continues this at home, her fifth finger is usually of an appropriate size” [3,25]. In the original depiction of the “cutback operation” by Wilkins, it states: “One blade of scissors was placed in the fistula and the other across the perineum.” “Due to the fistula passing through the limbs of the puborectalis sling, if a sufficiently wide passage was created through dilation, the child achieved continence” [4]. This procedure yielded positive functional outcomes in both male and female children with perineal and vestibular fistulas. For instance, Browne wrote, “Once it is understood that the vaginal opening is a true anus, complete with nerve and muscle sphincter mechanisms, albeit misplaced and often stenotic, treatment becomes more manageable and successful” [36]. “The treatment involves a rearward incision, extending well beyond the normal anal site, followed by extended dilation.” “However, if the opening is situated deep within the vaginal orifice, a backward transplantation can be conducted, preferably between ages 5 to 7 years” [36]. Despite the posterior incision resulting in the normal functioning of the anorectum, some surgeons treating vestibular fistulas, due to cosmetic concerns, started resorting to anorectoplasty, repositioning the isolated “fistula” to the center of the ring of subcutaneous part of the EAS [4,37].

## Disadvantages of the cutback procedure that may cause chronic constipation.

Prolonged bougienage of the displaced anus each time causes a rupture in the connective tissue septa that developed after the previous stretching. This procedure is painful, leading to the perpetuation of the inflammatory process and the formation of fibrous tissue. Within 3 months of bougienage, a wide opening can be created, but it won’t be elastic

enough to naturally continue expanding in parallel with the child's growth and proportional to the rectal widening. This complication can result in chronic constipation, as described by Kyrklund et al. [25].

In some patients with vestibular ectopia after the cutback procedure, the anus is situated very close to the vagina, presenting a significant aesthetic defect, despite a positive functional outcome. This accounts for pediatric surgeons opting for anorectoplasty over this operation, despite the notable loss of anorectal function. Although the potential risk of urinary tract inflammation due to the proximity of the urethral and anal openings is often cited as an additional reason for avoiding the cutback procedure, no evidence of this complication has been reported yet.

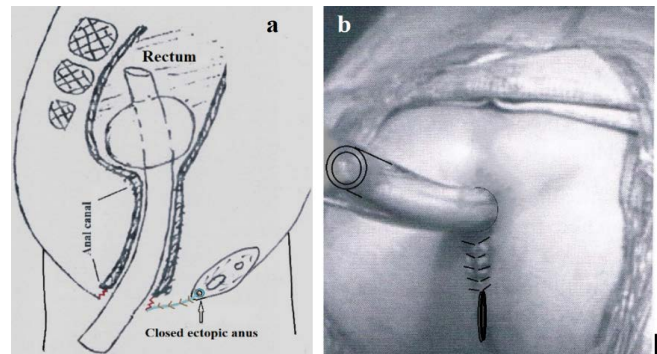
### Modification of the Cutback Procedure

The main part of the operation is conducted as originally proposed. One blade of the scissors is inserted into the fistula towards the anal fossa, while the other blade remains outside. The skin, subcutaneous tissue, and the wall of the EAC, along with the mucosa, are dissected with scissors until the annulus of the subcutaneous part of the EAS is transected into two parts by diameter. The length of the incision should be adequate so that the axis of the tube inserted into the rectum aligns with the axis of the anal canal.

To promptly achieve the required diameter of the anus without prolonged painful bougienage, we propose the insertion of a tracheostomy tube with a diameter of 1.3 to 1.5 cm into the rectum, based on the child's age. Inside the rectum, the balloon of the tracheostomy tube is inflated to a diameter of 3-4 cm, allowing the tube to remain in the rectum for two weeks along the axis of the anal canal. This suggestion draws from the experiences of Haly Abbas (949-982 AD), who recommended "to insert a piece of lint or lead tube for some days to avoid stricture..." (quoted from Iranikhah et al. [38]). Our own experience supports the viability of this approach. We introduced a tracheostomy tube into the rectum after perineal perforation in four neonates with ARM and no visible fistula. While we didn't suture the IAS to the skin, diastasis healed without inflammation or scarring in the three surviving patients. Fecal retention and defecation in these cases did not differ from healthy children [39].

For females with vestibular ectopy, the insertion of a tube into the anal canal addresses another issue - relocating the newly created anus away from the vestibule. The perineal incision closed with separate sutures from the dissected ectopic anus to the tube (Figure 2).

Following the surgery, diastasis occurs (2-4 mm - red angular line) between the IAS and the perineal skin. For a span of 2 weeks, bowel movements take place through a tube, the tip of which resides in the rectum. The tracheostomy tube



**Figure 2:** Schemes of Modification of the Cutback Procedure in ARM with Vestibular Ectopia. **(a) Central sagittal plane.** Initially, the skin, subcutaneous tissue, and wall of the IAS are incised between the scissor blades from the location of the ectopic anus in the vestibule of the vagina (arrow) to the complete intersection of the annulus of the subcutaneous part of the EAS. A tracheostomy tube is inserted into the rectum. At its end, a balloon is inflated to secure the tube in the anal canal. The skin with subcutaneous tissue is closed with single sutures from the ectopic anus to the anterior wall of the tube (blue line). **(b) Front view.**

is taken out after this two-week period. During this duration, due to the regeneration of the IAS, the diastasis between the IAS wall and the skin seals shut. If the operation was performed shortly after birth, the width of the newly created anus permits the normal emptying of the rectum, and the absence of fibrous tissue contributes to the anus expanding with age, like the condition in healthy individuals. If the operation was performed after the onset of constipation and a megarectum has already occurred, it is necessary to do cleansing enemas 1-2 times a week and, in case of abundant fecal discharge, perform digital bougienage of the anus 1 time per week under the supervision of a pediatric surgeon.

### Conclusion

An analysis of histological, manometric, and radiological studies on the pathophysiology of ARM with visible fistulas (perineal and vestibular) indicates the presence of a normally functioning anal canal. When the same method is employed to evaluate postoperative results, it becomes evident that after the cutback procedure, wherein all elements of the anal canal are preserved, favorable outcomes are observed in 70-90% of cases, with an actual absence of poor results. Following PSARP, during which the anal canal is disrupted, nearly all patients experience more frequent poor results and less frequent fair results. We have substantiated the modification of the cutback procedure, which facilitates the postoperative management of the patient (excluding bougienage of the newly created anus) and prevents the development of chronic constipation. It is designed to displace of the anus away from the vestibular, which provides a good aesthetic appearance of the perineum and prevents contamination of the vaginal vestibule.

## References

- Stephens FD. Imperforate rectum. A new surgical technique. *Medical Journal of Australia* 1 (1953): 202.
- Ito Y, Yokoyama J, Hayashi A, et al. Reappraisal of endorectal pull-through procedure. I. Anorectal malformations. *Journal of Pediatric Surgery* 16 (1981): 476-483.
- Nixon HH. Anorectal anomalies: with an international proposed classification. *Postgraduate Medical Journal* 48 (1972): 465-470.
- Wilkinson AW. Congenital anomalies of the anus and rectum. *Archives of Disease in Childhood* 47 (1972): 60-969.
- Scott JE. The microscopic anatomy of the terminal intestinal canal in ectopic vulval anus. *Journal of Pediatric Surgery* 1 (1966): 441-445.
- Swain VA, Tucker SM. The results of operation in 46 cases of malformation of the anus and rectum. *Gut* 3 (1962): 245-251.
- Peña A, Devries PA. Posterior sagittal anorectoplasty: important technical considerations and new applications. *Journal of Pediatric Surgery* 17 (1982): 796-811.
- Levitt MA, Peña A. Anorectal malformations. *Orphanet Journal of Rare Diseases* 2 (2007): 33. Erratum in: *Orphanet Journal of Rare Diseases* 7, 98.
- Duhamel B. Physio-pathology of the internal anal sphincter. *Archives of Disease in Childhood* 44 (1969): 377-381.
- Lambrecht W, Lierse W. The internal sphincter in anorectal malformations: morphologic investigations in neonatal pigs. *Journal of Pediatric Surgery* 22 (1987): 1160-1168.
- Ohama K, Asano S, Nanbu K, et al. The internal anal sphincter in anorectal malformation. *Zeitschrift für Kinderchirurgie* 45 (1 990): 167-177.
- Rintala R, Lindahl H, Sariola H, et al. The rectourogenital connection in anorectal malformations is an ectopic anal canal. *Journal of Pediatric Surgery* 25 (1990): 665-668.
- Uemura K, Fukuzawa H, Morita K, et al. Epithelial and ganglionic distribution at the distal rectal end in anorectal malformations: could it play a role in anastomotic adaptation? *Pediatric Surgery International* 37 (2021): 281-286.
- Gowers WR. The autonomic action of the sphincter ani. *Proceedings of the Royal Society of London* 26 (1877): 77-81.
- Tobon F, Schuster MM. Megacolon: special diagnostic and therapeutic features. *Johns Hopkins Medical Journal* 135 (1974): 91-105.
- Bharucha AE. Pelvic floor: anatomy and function. *Neurogastroenterology & Motility* 18 (2006): 507-519.
- Palit S, Lunniss P, Scott SM. The physiology of human defecation. *Digestive Diseases and Sciences* 57 (2012): 1445-1464.
- Levin MD. Rentgenofunktsional'nye issledovaniia pri éktopii anal'nogo kanala u detei [Roentgeno-functional studies in ectopia of the anal canal in children]. *Vestnik Rentgenologii i Radiologii* (1989): 10-16. [Bulletin of Radiology and Radiology].
- Ruttenstock EM, Zani A, Huber-Zeyringer A, et al. Preand postoperative rectal manometric assessment of patients with anorectal malformations: should we preserve the fistula? *Diseases of the Colon and Rectum* 56 (2013): 499-504.
- Levin MD. Anatomy and physiology of anorectum: The hypothesis of fecal retention, and defecation. *Pelvipерineology* 40 (2021): 50-57.
- Levin MD. Radiological anatomy of the colon and rectum in children. *Gastroenterology & Hepatology* 10 (2019): 82-86.
- Amerstorfer EE, Schmiedeke E, Samuk I, et al. Clinical Differentiation between a Normal Anus, Anterior Anus, Congenital Anal Stenosis, and Perineal Fistula: Definitions and Consequences-The ARM-Net Consortium Consensus. *Children (Basel)* 9 (2022): 831.
- Levin MD. Pathophysiology and diagnosis of descending perineum syndrome in children. *Pelvipерineology* 37 (2018): 52-56.
- Ackroyd R, Nour S. Long-term faecal continence in infants born with anorectal malformations. *Journal of the Royal Society of Medicine* 87 (1994): 695-696.
- Kyrklund K, Pakarinen MP, Taskinen S, et al. Bowel function and lower urinary tract symptoms in males with low anorectal malformations: An update of controlled, long-term outcomes. *International Journal of Colorectal Disease* 30 (2015): 221-228.
- de la Fuente AQ, Arance MG, Cortés L. Low ano-rectal malformations. *Anales Españoles de Pediatría* 12 (1979): 603-606.
- Stenström P, Kockum CC, Emblem R, et al. Bowel symptoms in children with anorectal malformation - a follow-up with a gender and age perspective. *Journal of Pediatric Surgery* 49 (2014): 1122-1130.

28. Levitt MA, Kant A, Peña A. The morbidity of constipation in patients with anorectal malformations. *Journal of Pediatric Surgery* 45 (2010): 1228-1233.
29. Lombardi L, Bruder E, Caravaggi F, et al. Abnormalities in “low” anorectal malformations (ARMs) and functional results resecting the distal 3 cm. *Journal of Pediatric Surgery* 48 (2013): 1294-1300.
30. Wood RJ, Halleran DR, Ahmad H, et al. Assessing the benefit of reoperations in patients who suffer from fecal incontinence after repair of their anorectal malformation. *Journal of Pediatric Surgery* 55 (2020): 2159-2165.
31. Eradi B, Hamrick M, Bischoff A, et al. The role of a colon resection in combination with a Malone appendicostomy as part of a bowel management program for the treatment of fecal incontinence. *Journal of Pediatric Surgery* 48 (2013): 2296-2300.
32. Wood RJ, Vilanova-Sanchez A, El-Gohary Y, et al. One-year impact of a bowel management program in treating fecal incontinence in patients with anorectal malformations. *Journal of Pediatric Surgery* 56 (2021): 1689-1693.
33. Kumar B, Kandpal DK, Sharma SB, et al. Single-stage repair of vestibular and perineal fistulae without colostomy. *Journal of Pediatric Surgery* 43 (2008): 1848-1852.
34. Koga H, Ochi T, Okawada M, et al. Comparison of outcomes between laparoscopy-assisted and posterior sagittal anorectoplasties for male imperforate anus with recto-bulbar fistula. *Journal of Pediatric Surgery* 49 (2014): 1815-1817.
35. Nixon HH, Puri P. The results of treatment of anorectal anomalies: A thirteen to twenty year follow-up. *Journal of Pediatric Surgery* 12 (1977): 27-37.
36. Browne D. Congenital deformities of the anus and the rectum. *Archives of Disease in Childhood* 30 (1955): 42-45.
37. Potts WJ, Riker WL, DeBoer A. Imperforate anus with recto-vesical, -urethral-vaginal and -perineal fistula. *Annals of Surgery* 140 (1954): 381-395.
38. Iranikhah A, Heydari M, Hakimelahi J, et al. Surgical Repair of Imperforate Anus: A Report from Haly Abbas (949-982AD). *Journal of Pediatric Surgery* 51 (2016): 192-193.
39. Levin MD. The pathological physiology of the anorectal defects, from the new concept to the new treatment. *Eksperimental'naya i Klinicheskaya Gastroenterologiya* [Experimental and Clinical Gastroenterology] 11 (2013): 38-48.